



Salivary Gland FNA and Histological Correlation

ASIF LOYA, MD

Consultant Pathologist

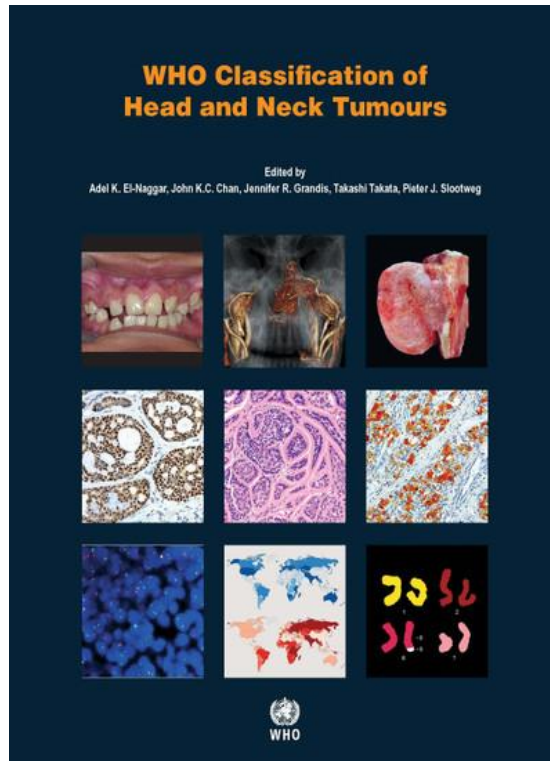
Medical Director

Shaukat Khanum Memorial Cancer Hospital and

Research Centre

Lahore, Pakistan

WHO Classification of Head & Neck Tumors 2016



WHO Classification of Head & Neck Tumors 2016

- Salivary Gland Tumors, new tumors recognized.
- ✓ Hyalinizing clear cell carcinoma of minor salivary glands
- ✓ Secretory carcinoma of salivary glands, previously known mammary analogue secretory carcinoma
- ✓ Cribriform adenocarcinoma of the tongue and minor salivary glands
- ✓ Intraductal carcinoma of salivary glands



WHO Classification of Head & Neck Tumors 2016

- Oropharynx as a distinctive sub-site
 - HPV related Squamous Cell Carcinoma, distinct entity
- New entities in Sino-Nasal Tract
 - NUT Carcinoma
 - HPV related carcinoma with adenoid cystic like features, also known as HPV related multiphenotypic sinonasal carcinoma



Effectiveness of Cytomorphology Salivary Gland Tumors

- SENSITIVITY: 86-100%
- ACCURACY:
 - Benign/low grade vs HG malignant: 81-98%
 - Specific lesion: 48-94%



Rationale for FNA

- Guide the clinical management/pre-op strategy:
 - Non-neoplastic Clinical follow up
 - Benign tumor/low-grade carcinoma Limited resection
 - Metastatic disease to parotid LNs LN resection
 - Lymphoma Heme-Onc referral
 - High-grade primary carcinoma Radical resection



FNA Diagnosis	ROM	Clinical Management/Pre-op Strategy
Non-Diagnostic	10-20%	Clinical/ Radiologic Correlation Repeat FNA
Non-Neoplastic	TBD (0-20%)	Clinical Follow-up Radiologic Correlation
AUS	TBD	Repeat FNA or Surgery
SUMP	20-40%	Conservative Surgery
Suspicious for Malignancy (LG vs HG)	70-80%	Surgery: Correlate LG vs HG
Malignant Neoplasm (ILG vs HG)	80-95%	Surgery: Correlate LG vs HG

Milan System for Reporting Salivary Gland Cytopathology, ED Rossi, Faquin WC, Cancer Cytopath.

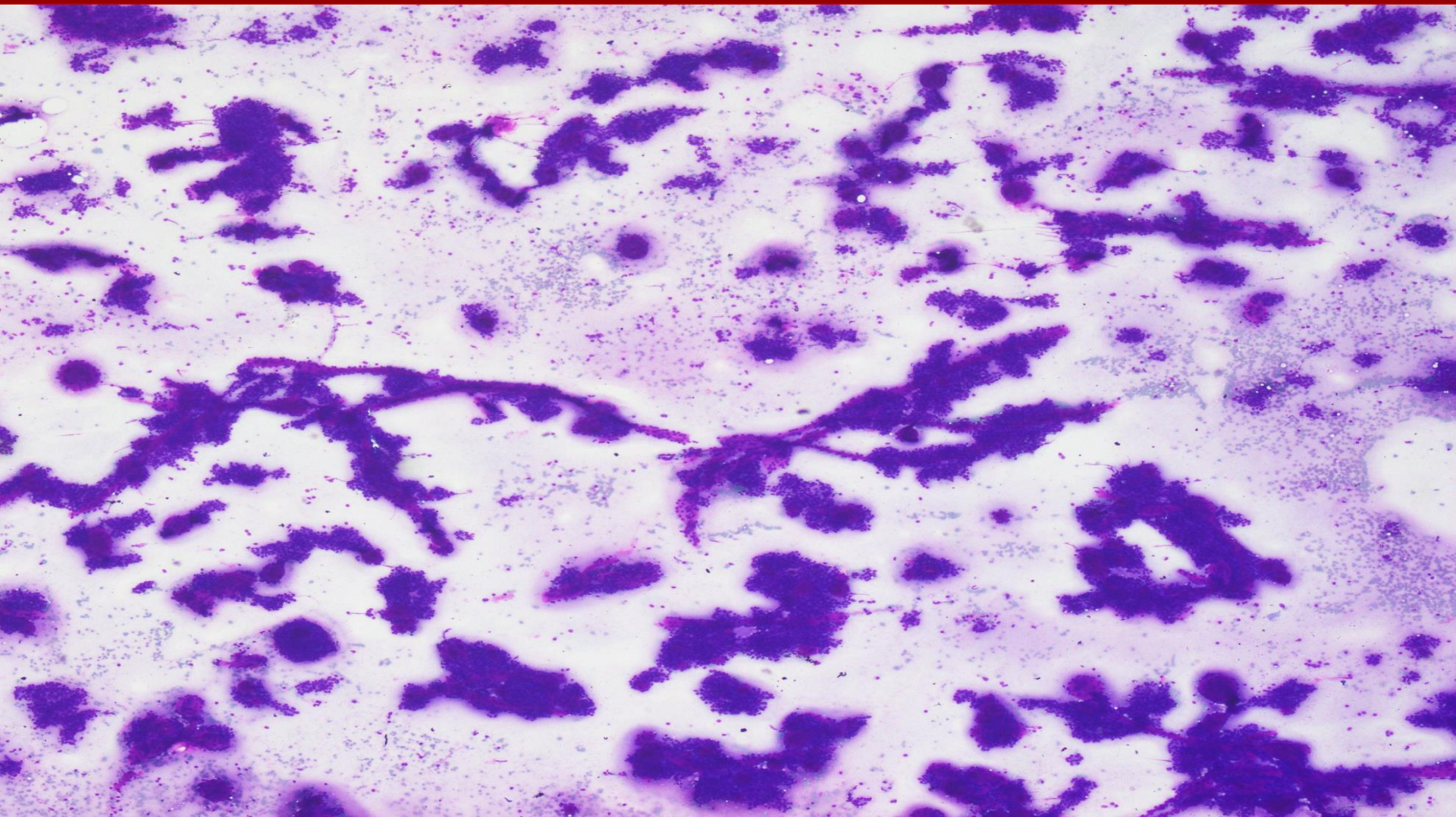


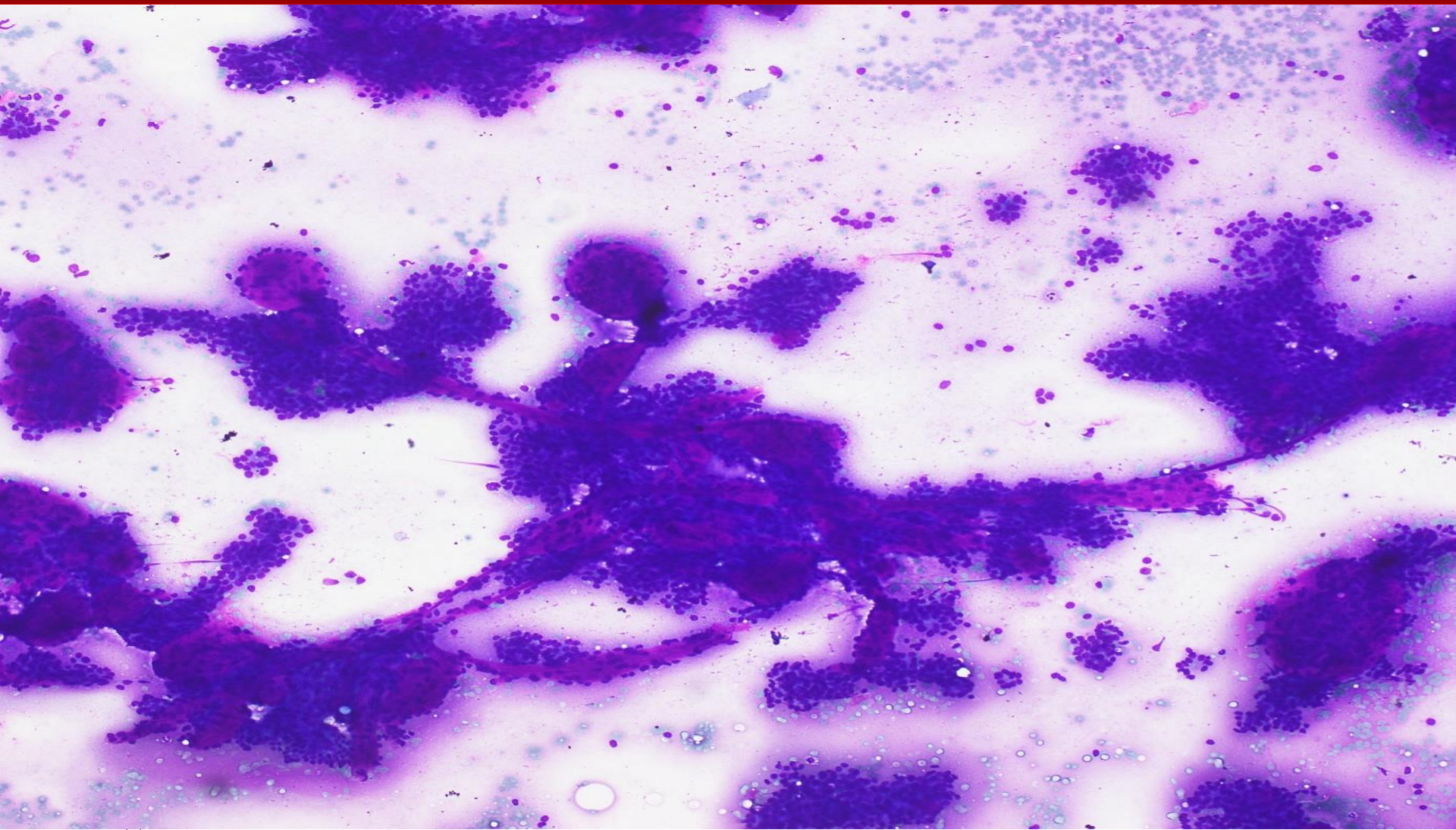
CASE NO 1

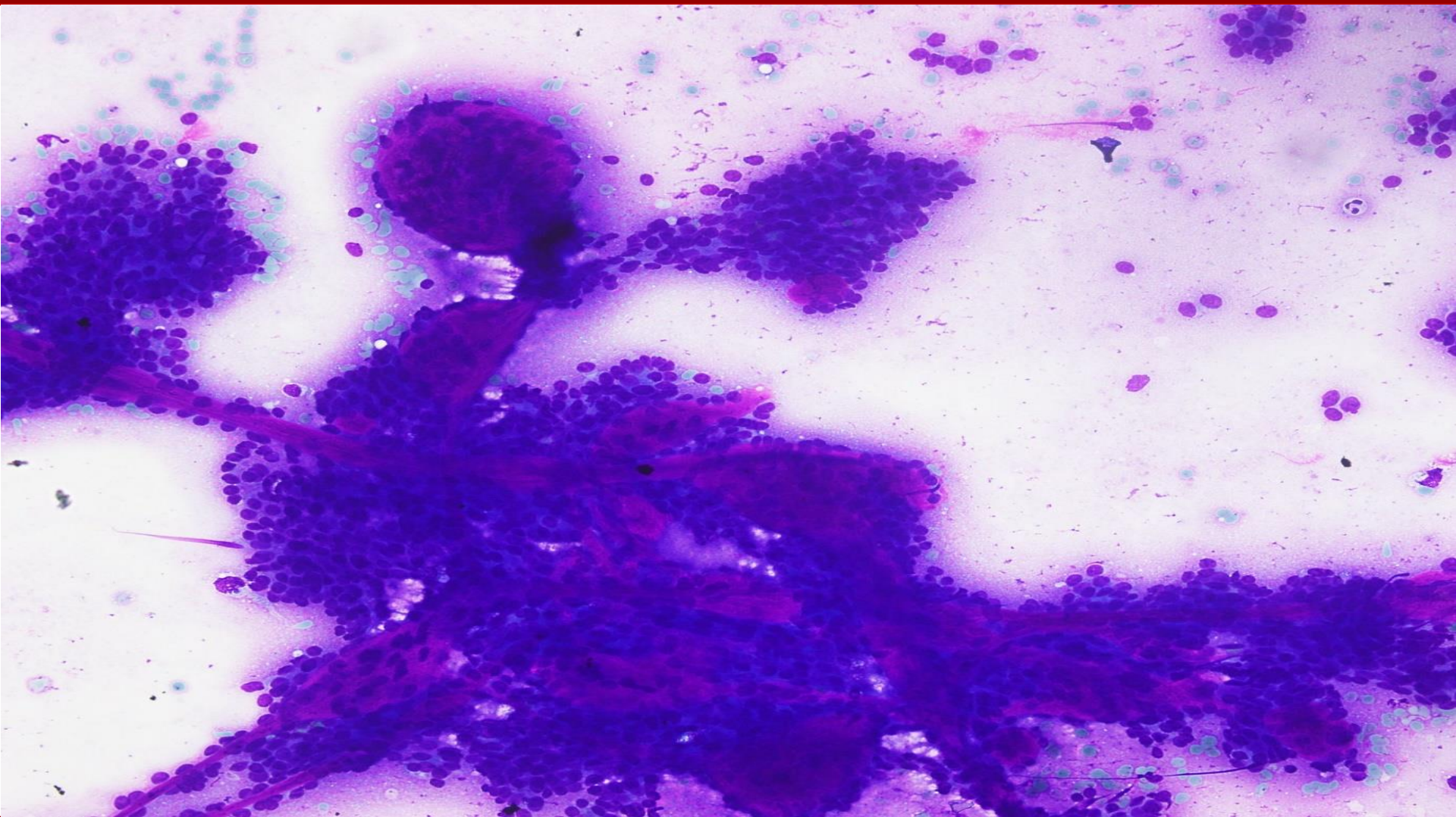
32 Female

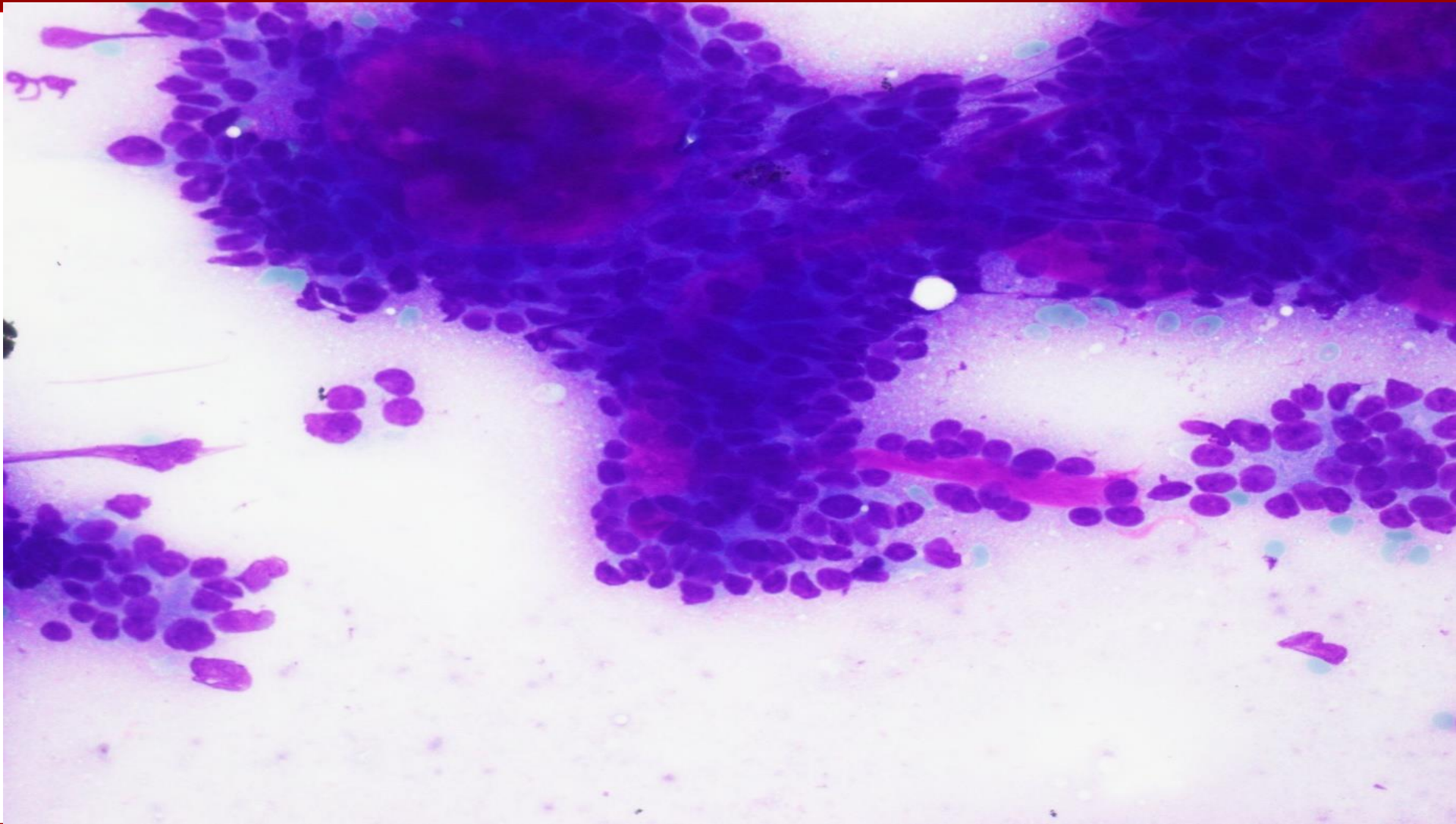
Left parotid gland swelling

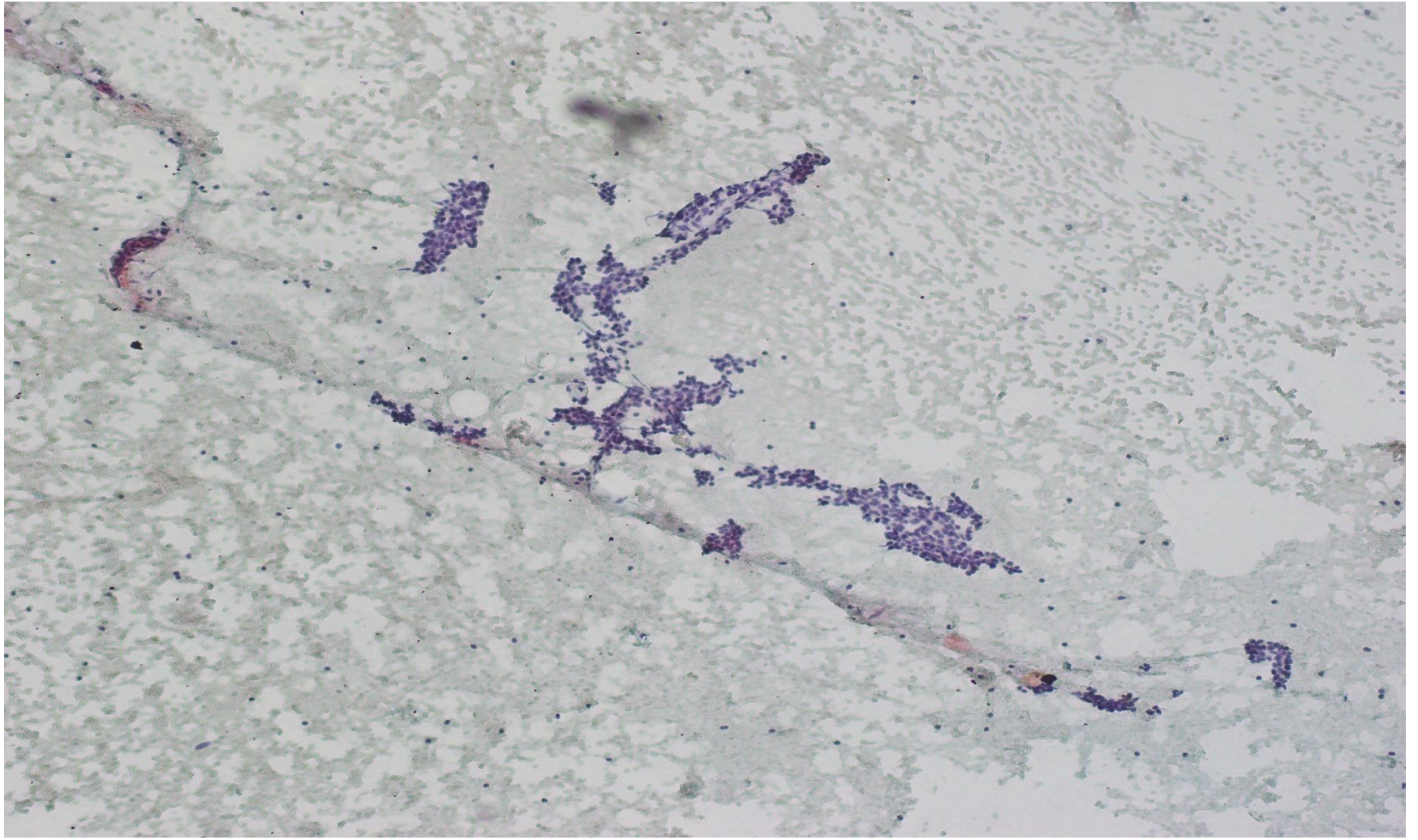


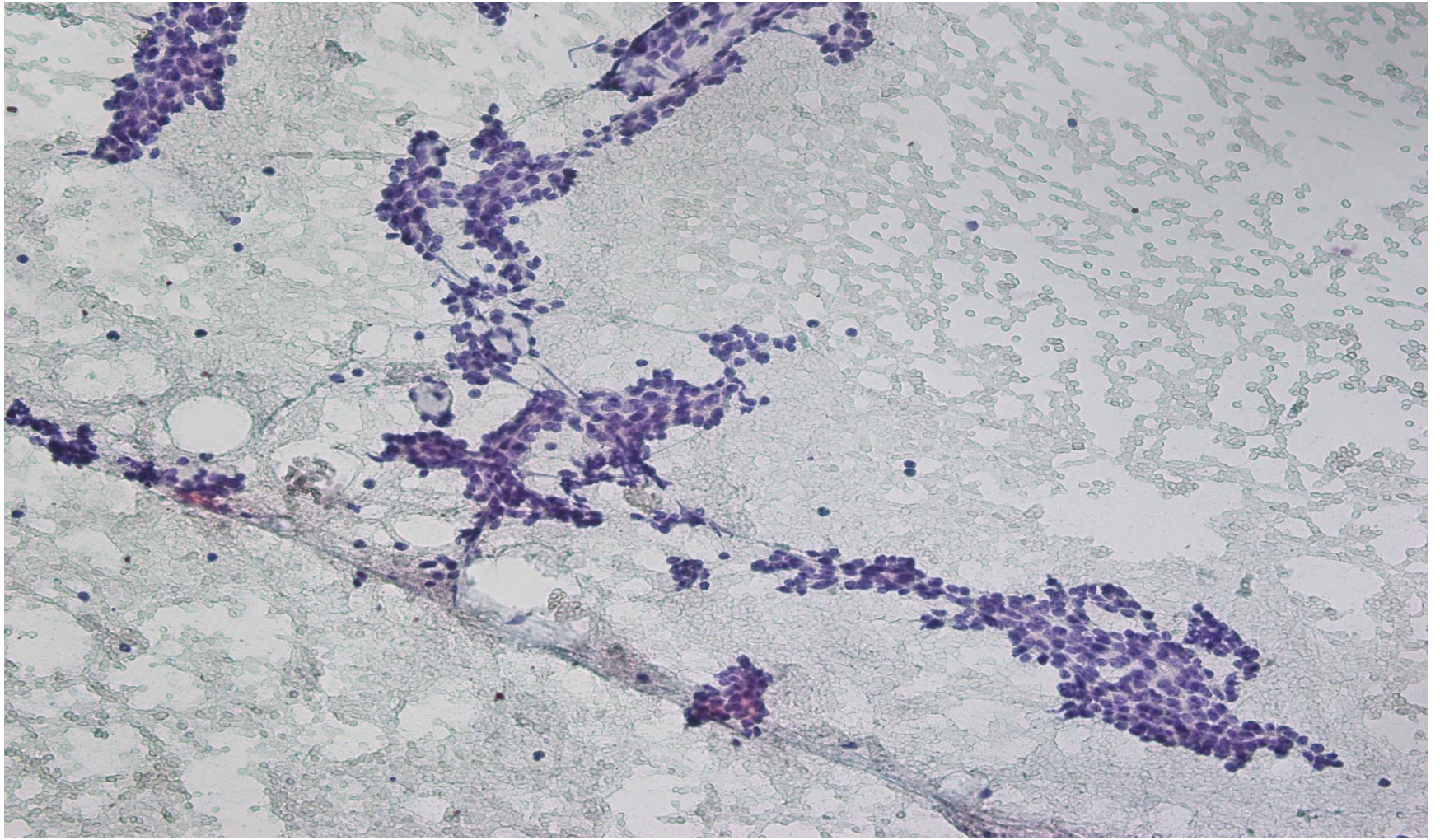


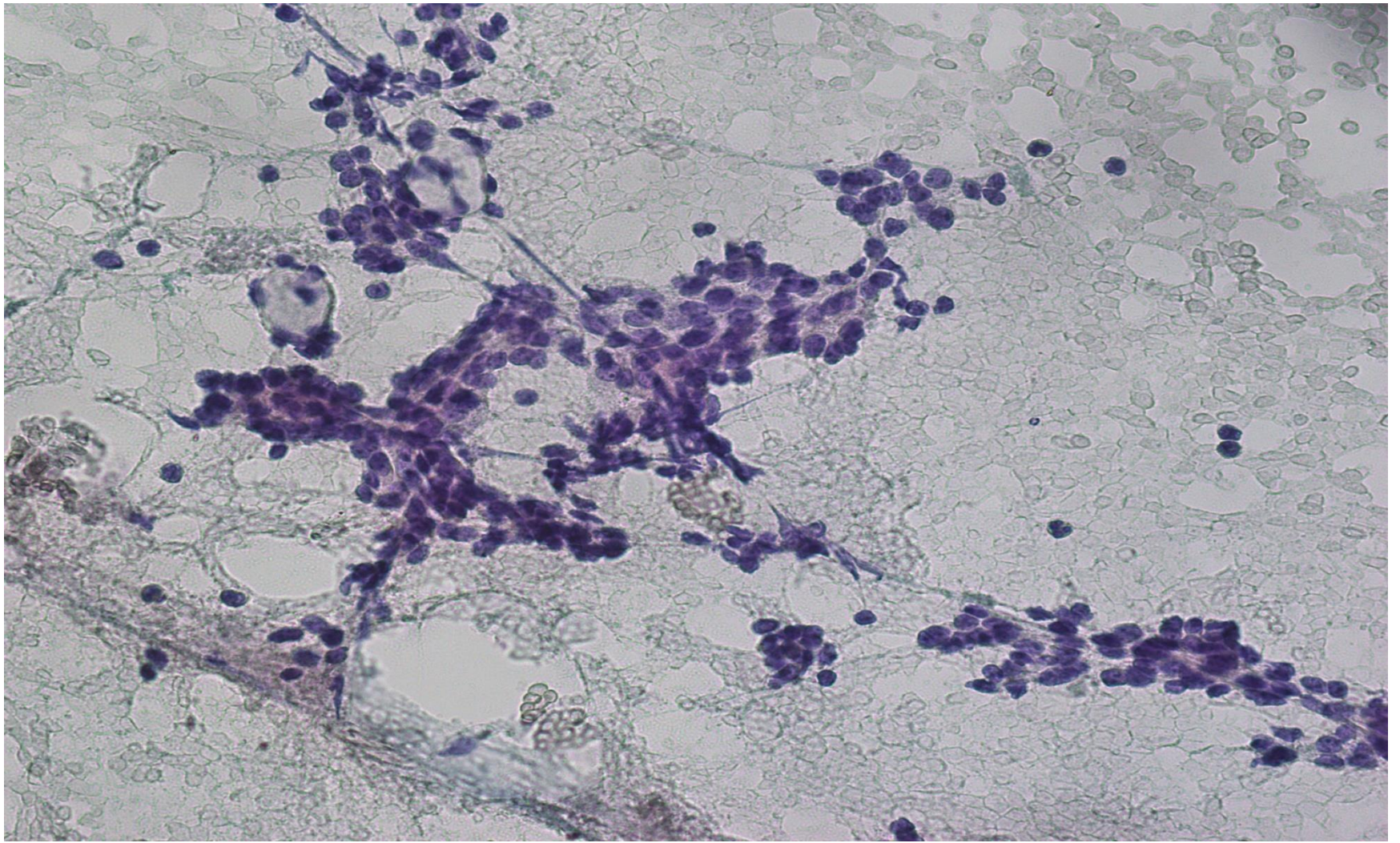












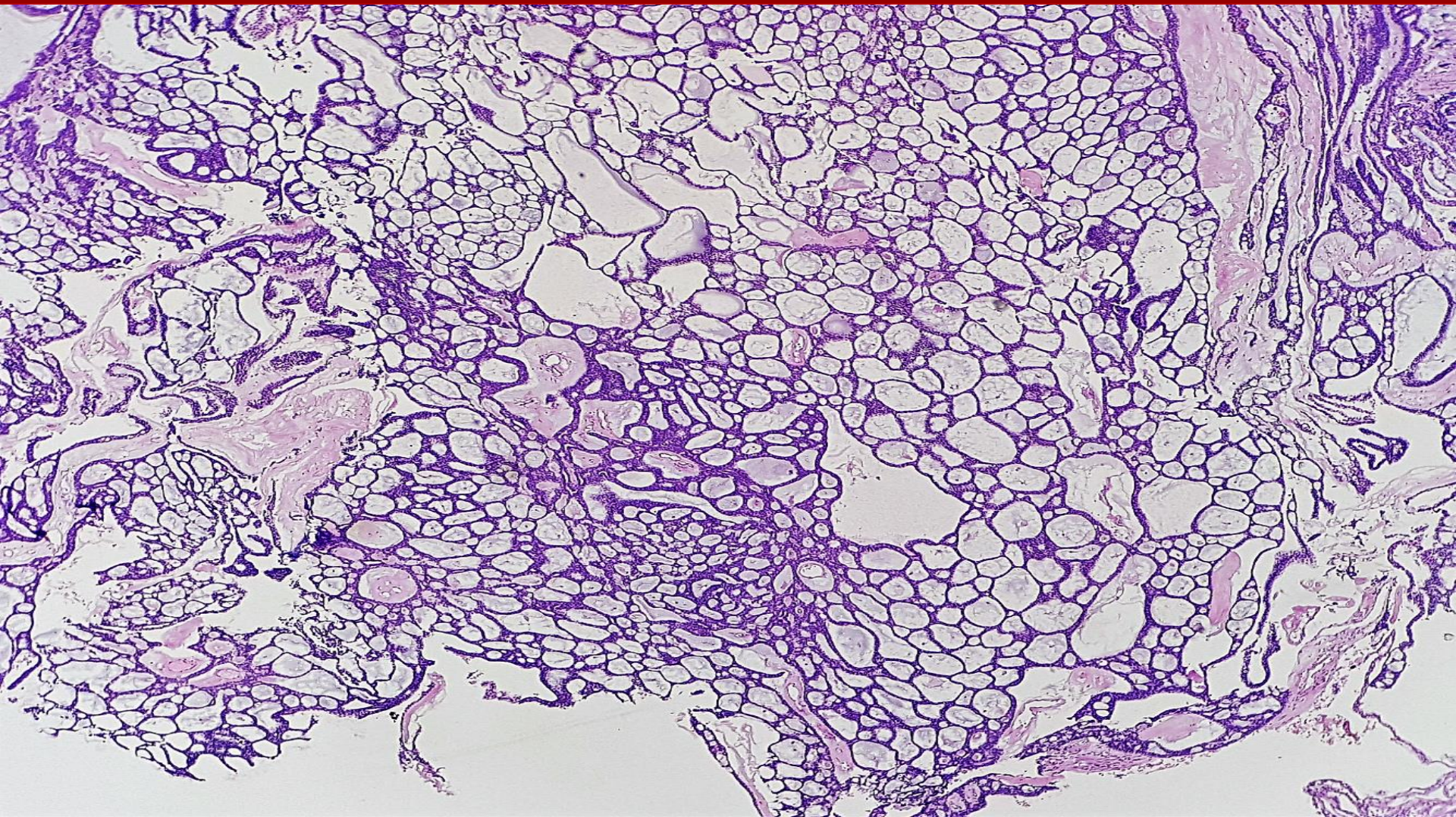
Differentials

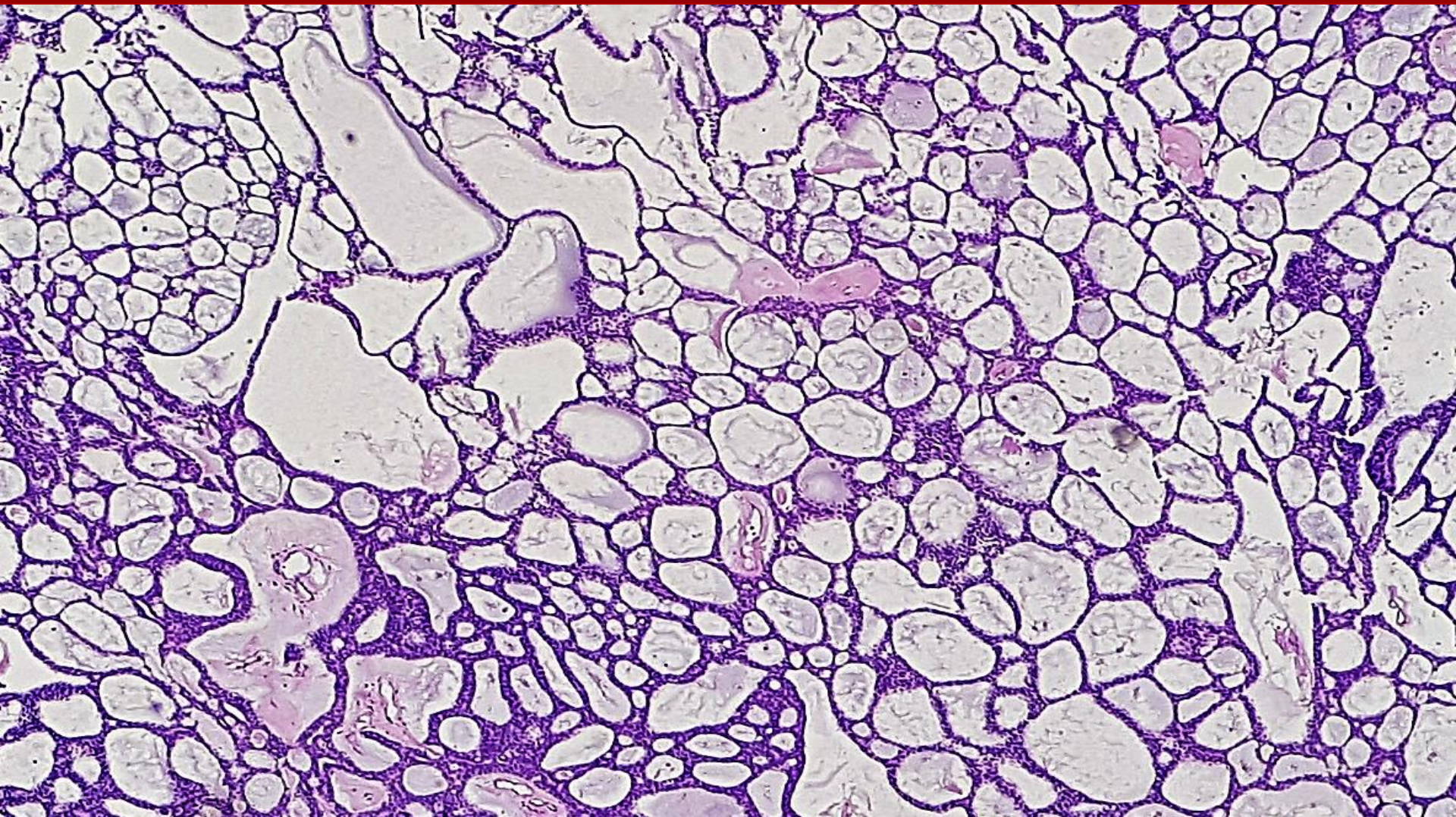
- Pleomorphic adenoma
- Basaloid neoplasms
- Polymorphous adenocarcinoma
- Epithelial-myoepithelial carcinoma
- Eccrine cylindroma of the skin
- Adenoid cystic carcinoma



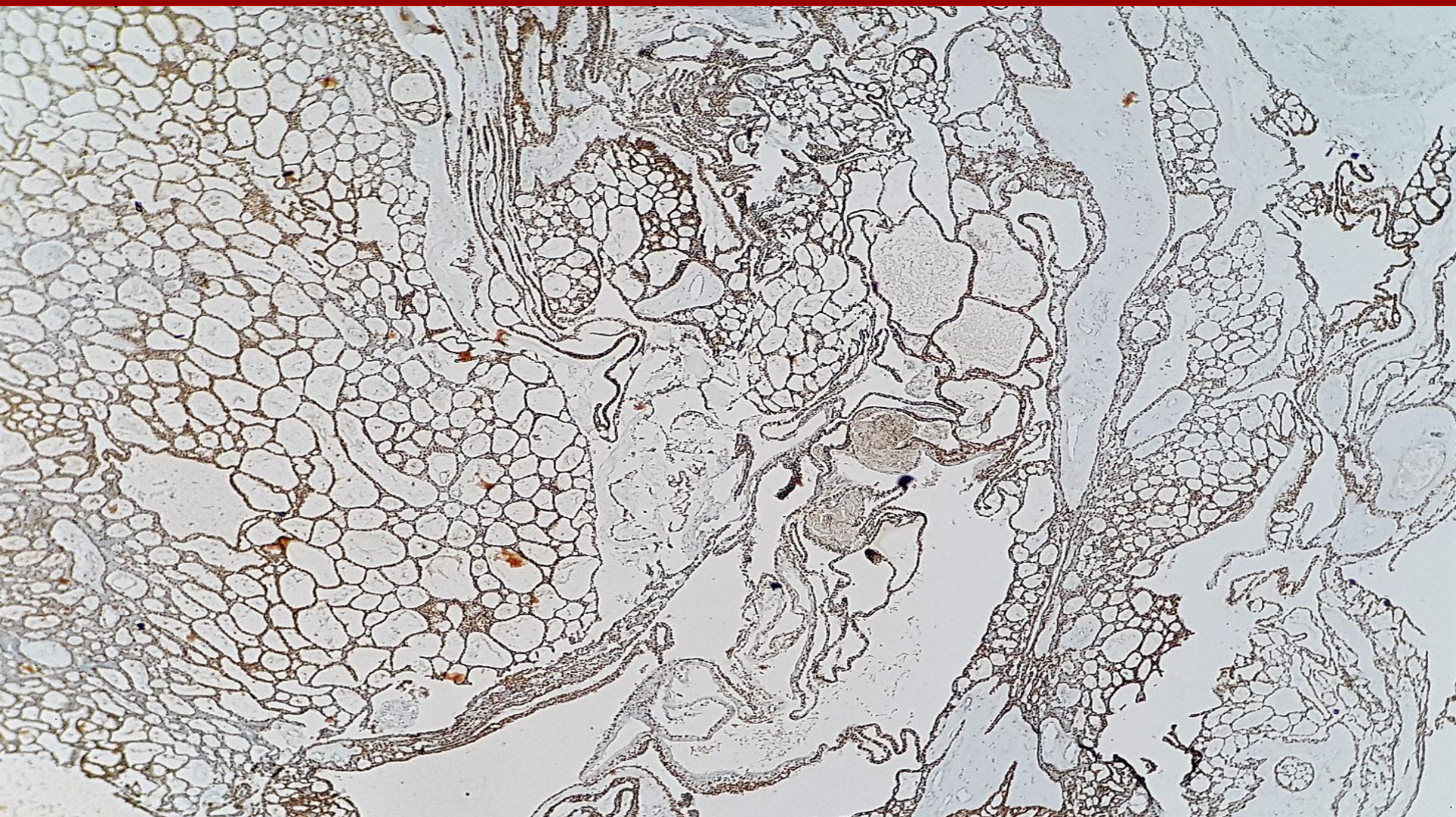
■ Adenoid Cystic Carcinoma



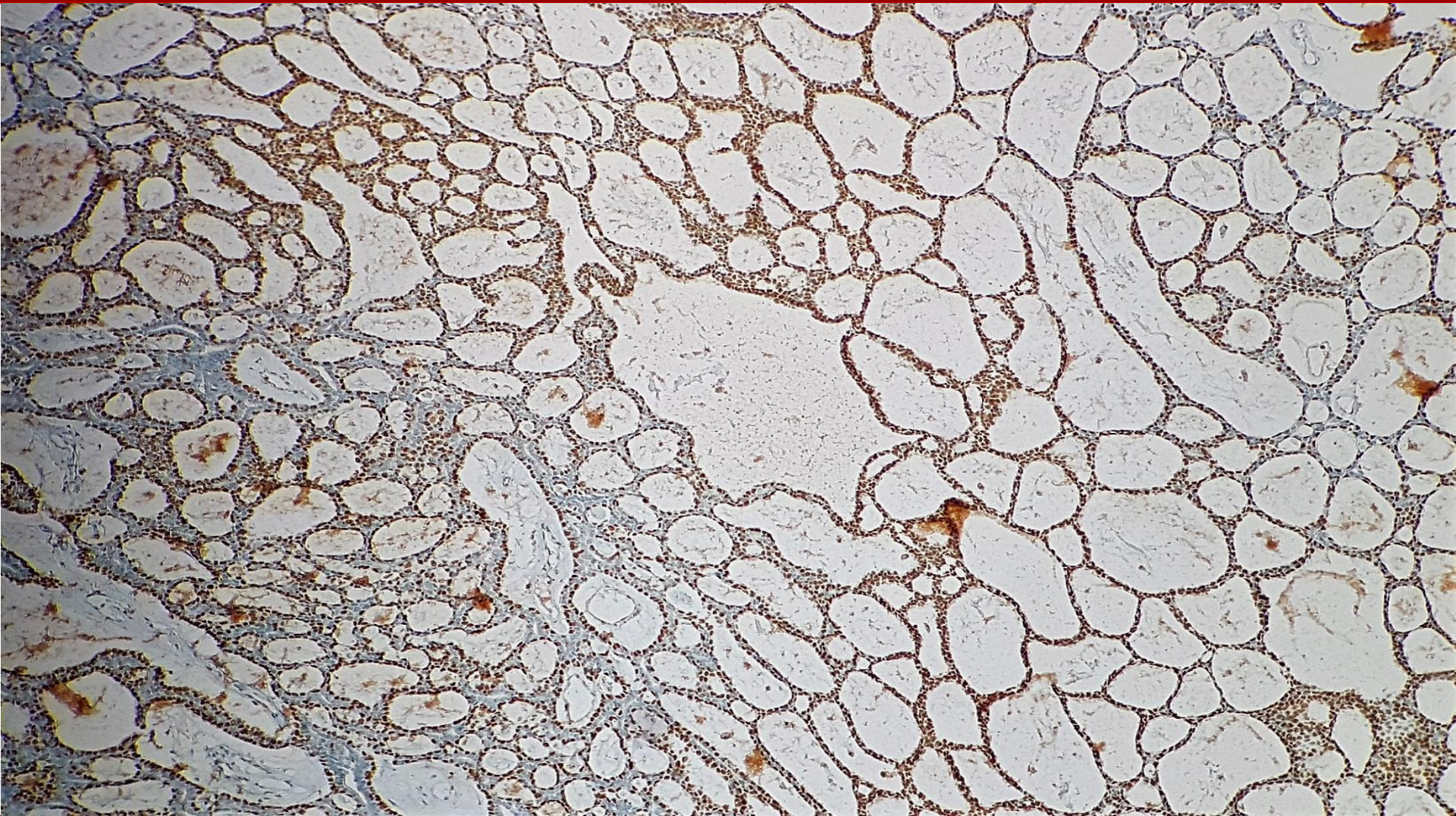




p63



p40



Adenoid cystic carcinoma, low grade



Immunohistochemistry

- **p63**-loss of myoepithelial differentiation in high grade/solid component
- **p40**-loss of myoepithelial differentiation in high grade/solid component
- **C-myb**- positive staining is helpful, sensitive but not specific
- **p16**- patchy staining is observed in high grade/dedifferentiated component
- **CK,CK7,EMA**-diffuse positive



UTILITY OF p63 AND p40 IN DISTINGUISHING POLYMORPHOUS ADENOCARCINOMA AND ADENOID CYSTIC CARCINOMA

Aribah Atiq, Sajid Mushtaq, Usman Hassan, Asif Loya, Mudassir Hussain, Noreen Akhtar (Submitted for publication)

		DIAGNOSIS		
		Adenoid cystic carcinoma	Polymorphous adenocarcinoma	
Combination 1	p63+ve/p40+ve	36(76%)	0	36
Combination 2	p63+ve/p40-ve	0	22(96%)	22
Combination 3	p63-ve/p40+ve	1(3%)	0	1
Combination 4	p63-ve/p40-ve	10(21%)	1(4%)	11
		47	23	70



On a retrospective analysis of all cases and comparison of immunoprofiles with architecture, it is seen that those cases of adenoid cystic carcinoma which showed p63-ve/p40-ve profile have high grade morphology and predominant solid pattern and this fact is also supported by another study by Gao Y. et al

Du F, Zhou CX, Gao Y. myoepithelial differentiation in cribriform, tubular and solid pattern of adenoid cystic carcinoma: A potential involvement in histological grading and prognosis.

Aanddiagpath.2016.03.001



Gene Alteration

- MYB/MYBL1-NFIB fusion

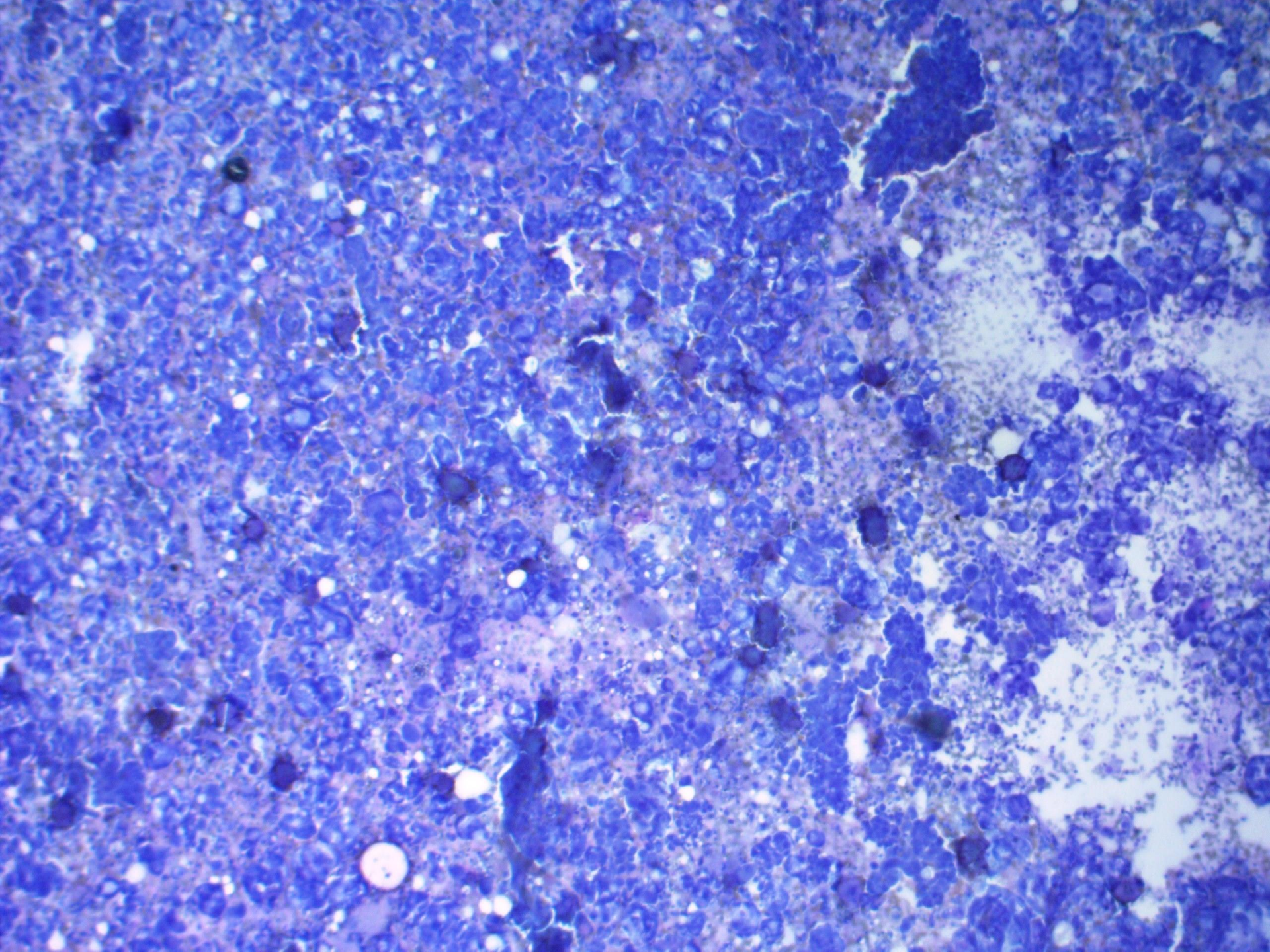


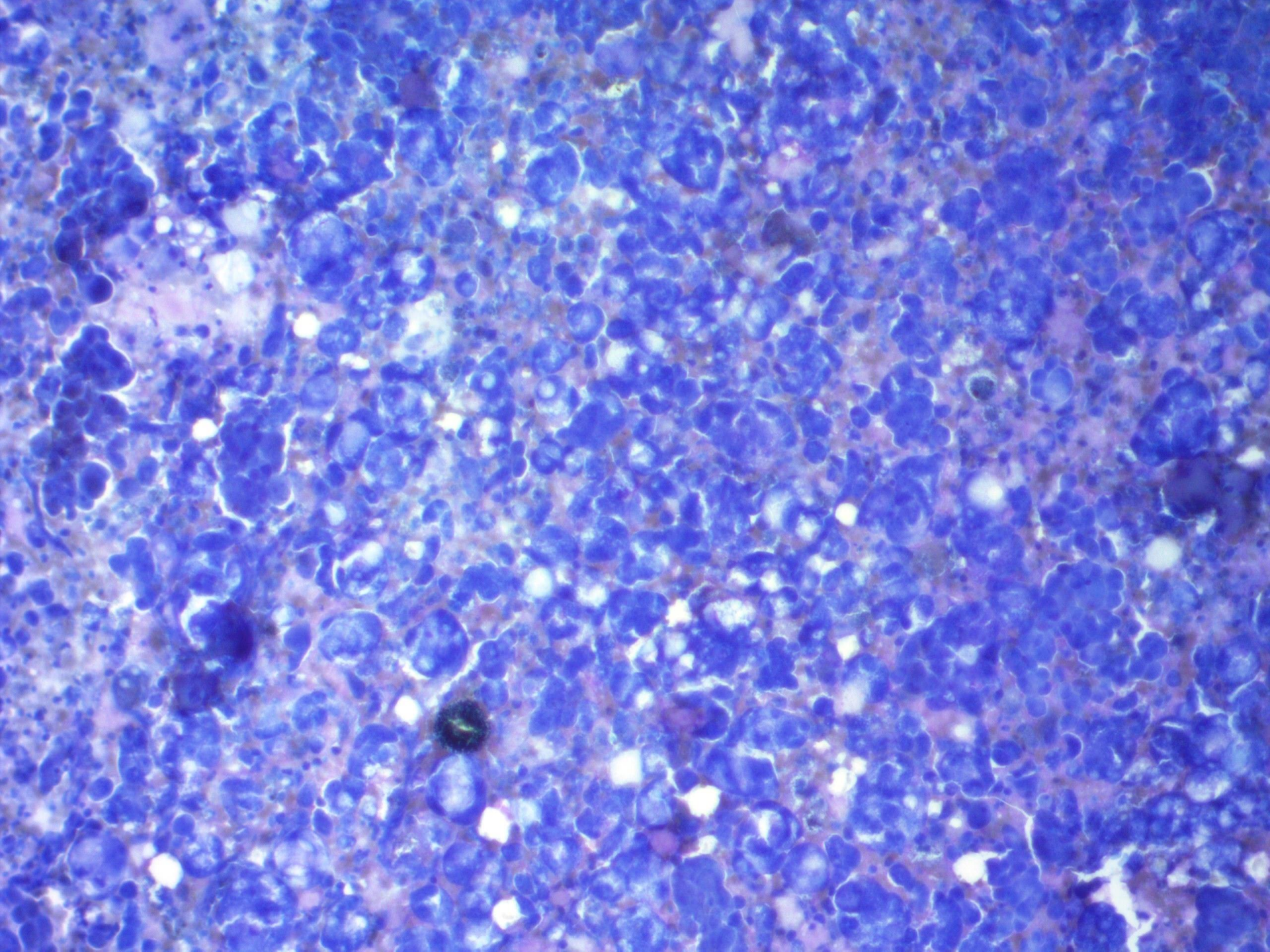
Case no. 2

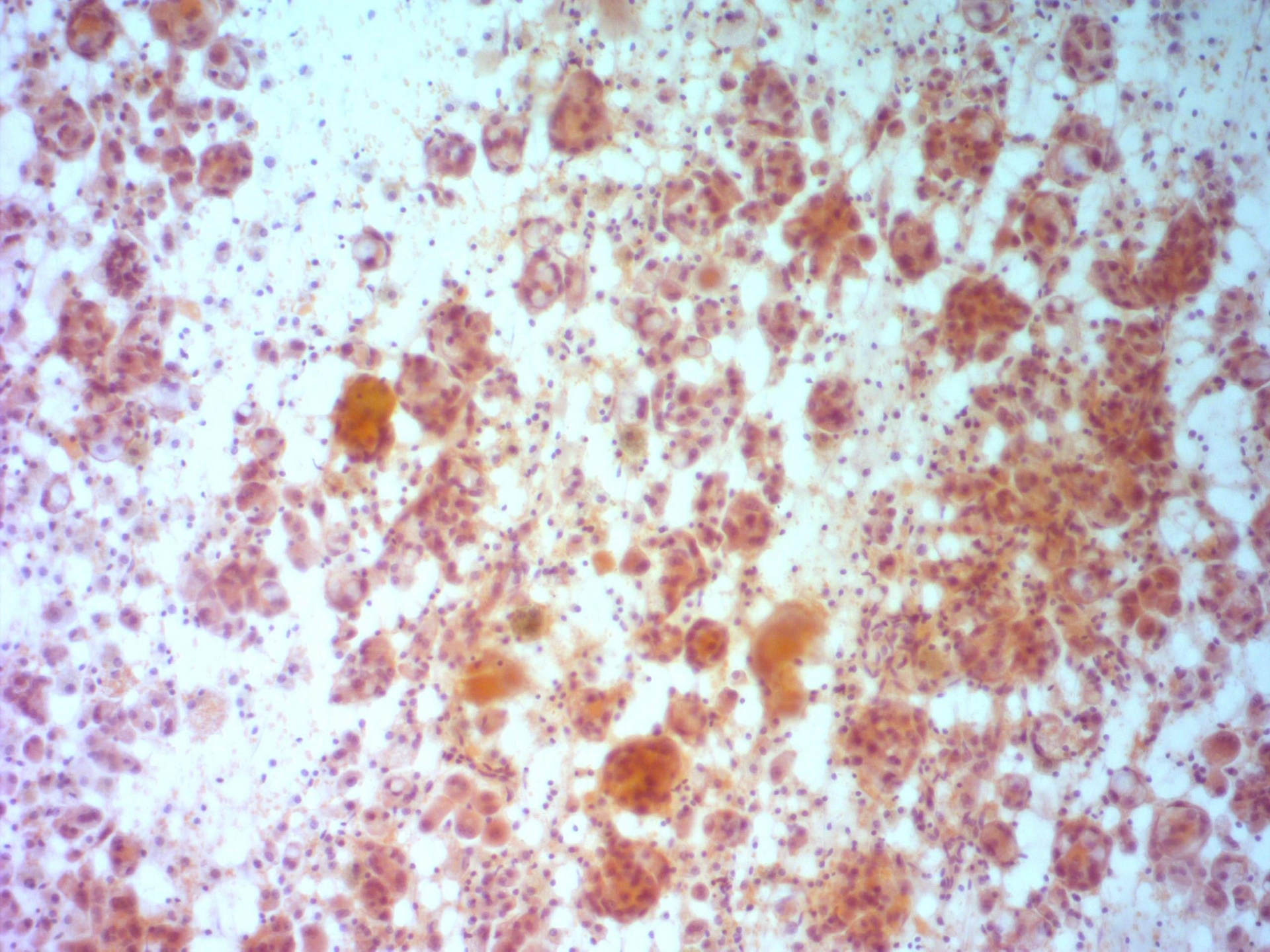
37 male

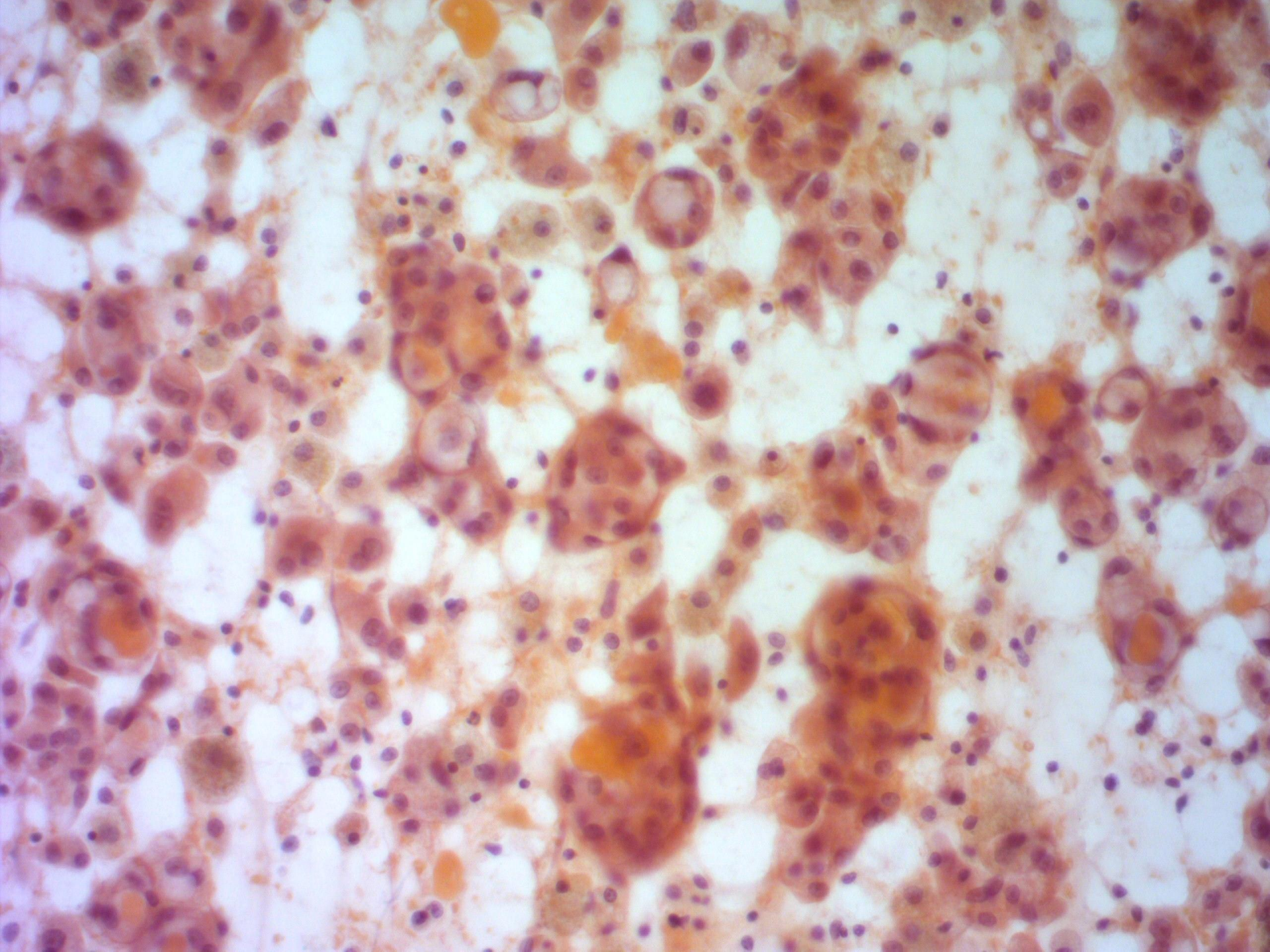
Parotid gland swelling



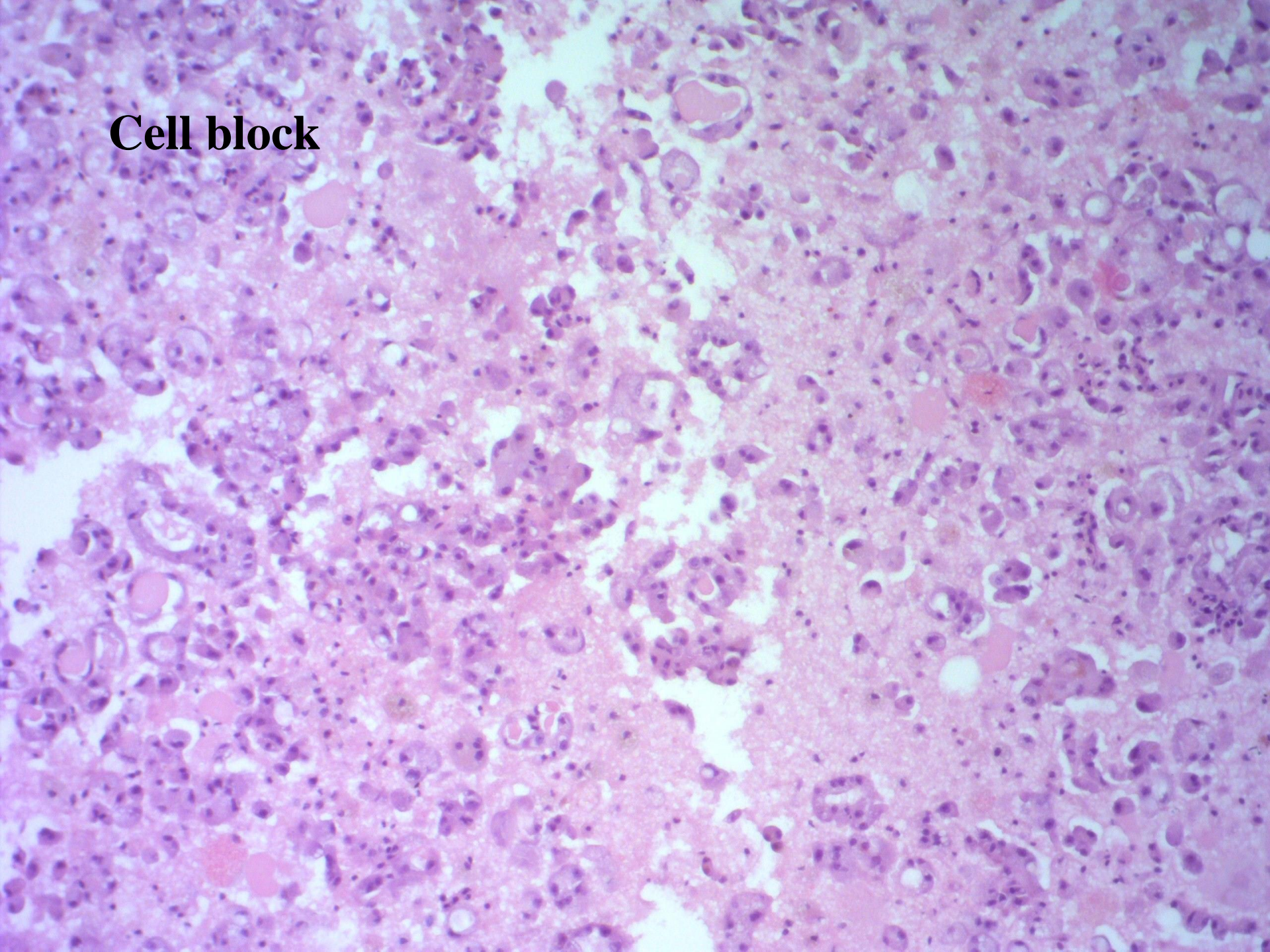








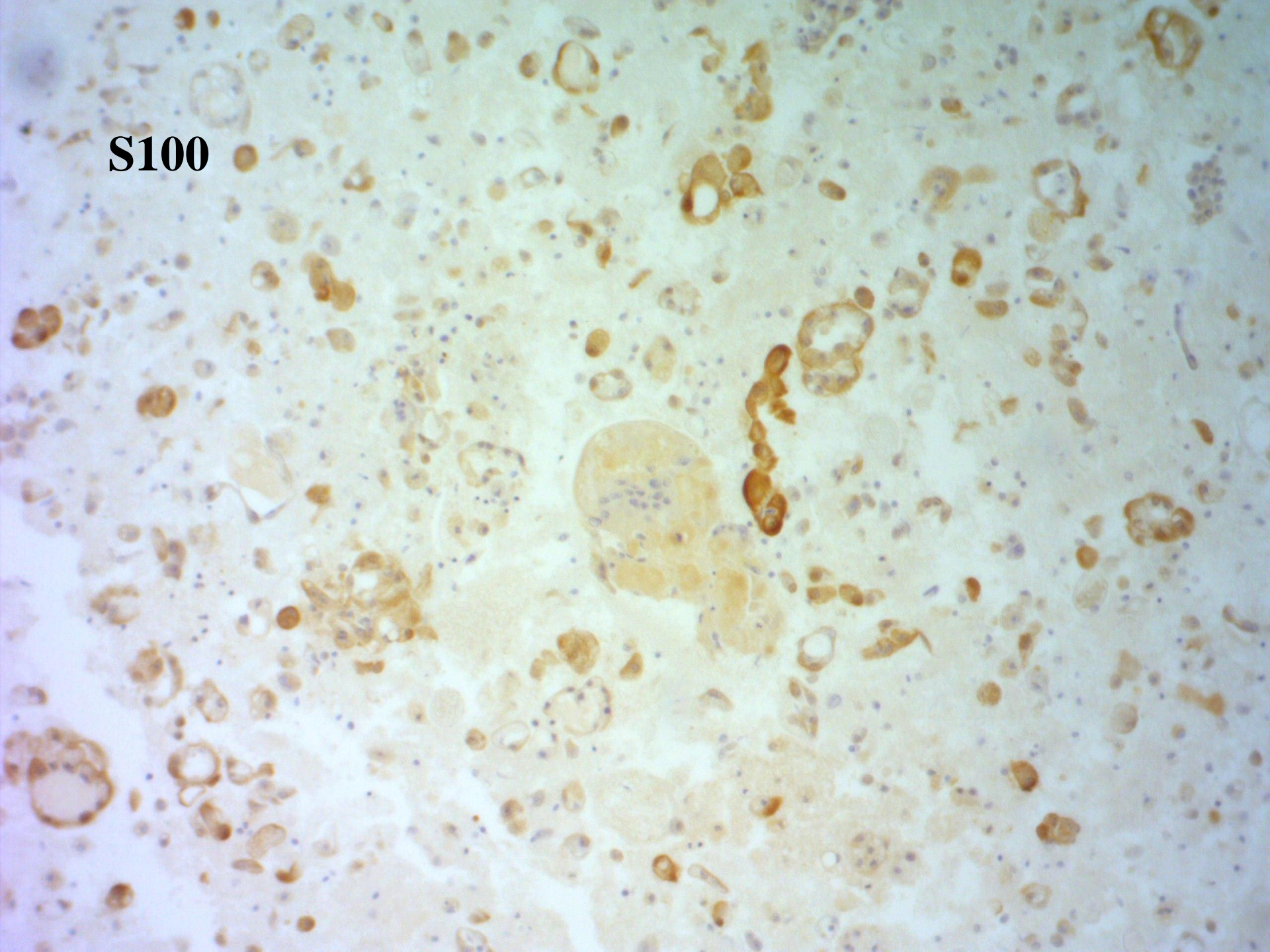
Cell block



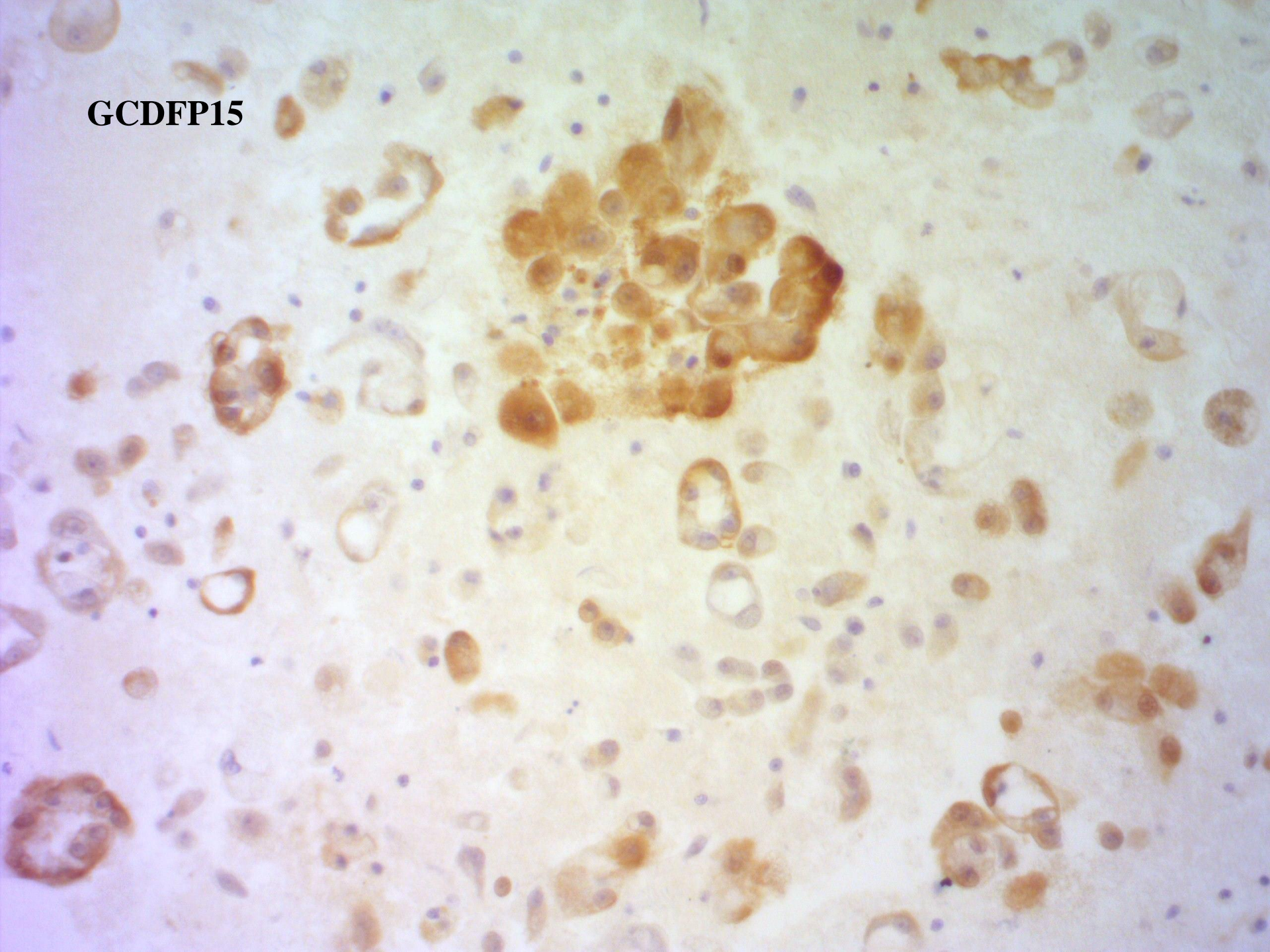
- Normal salivary gland
- Oncocytoma
- Secretory carcinoma of salivary gland (MASC)
- Warthin's tumor
- Acinic cell carcinoma
- Mucoepidermoid carcinoma
- Clear cell neoplasms



S100

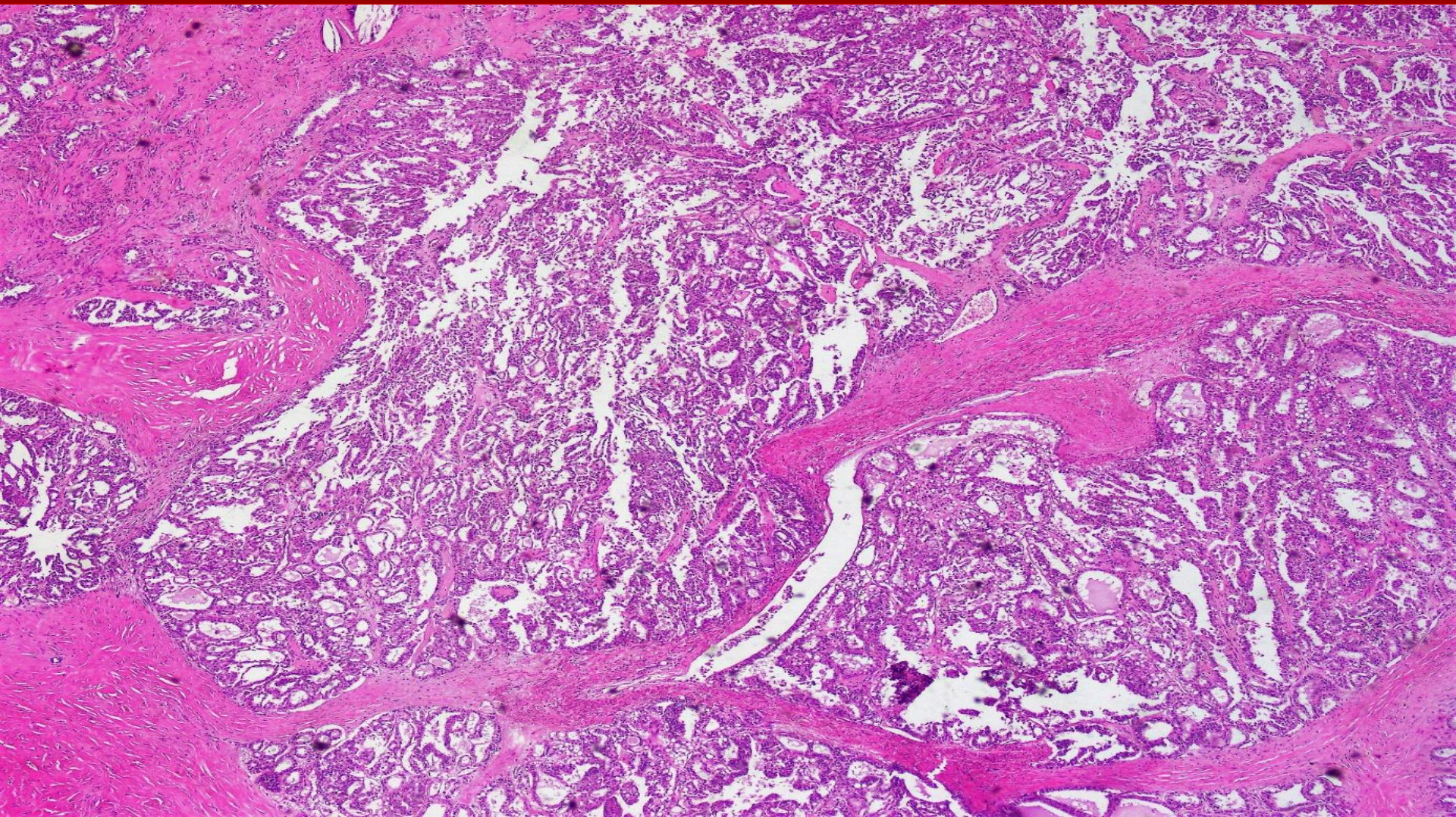


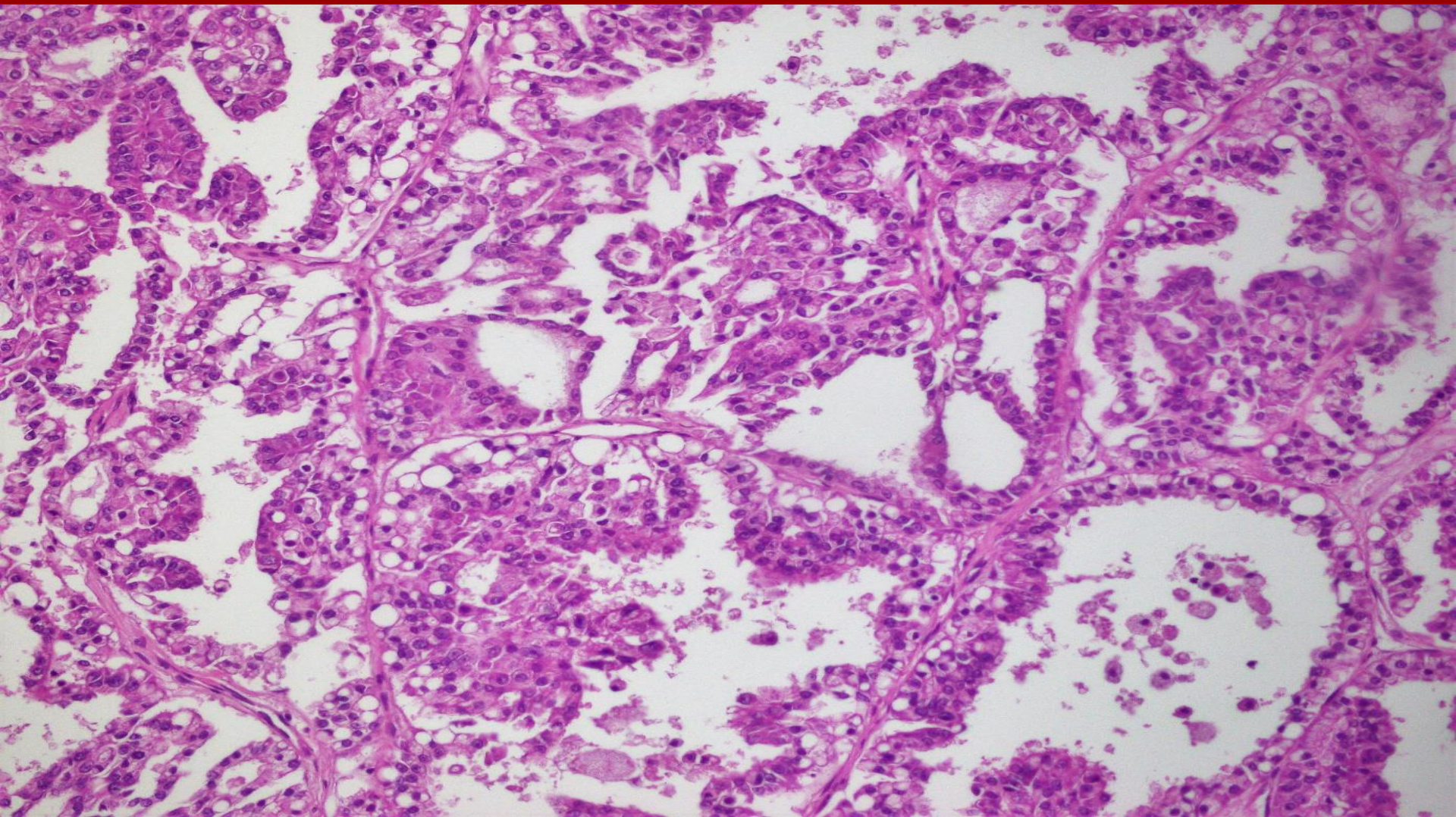
GCDFP15

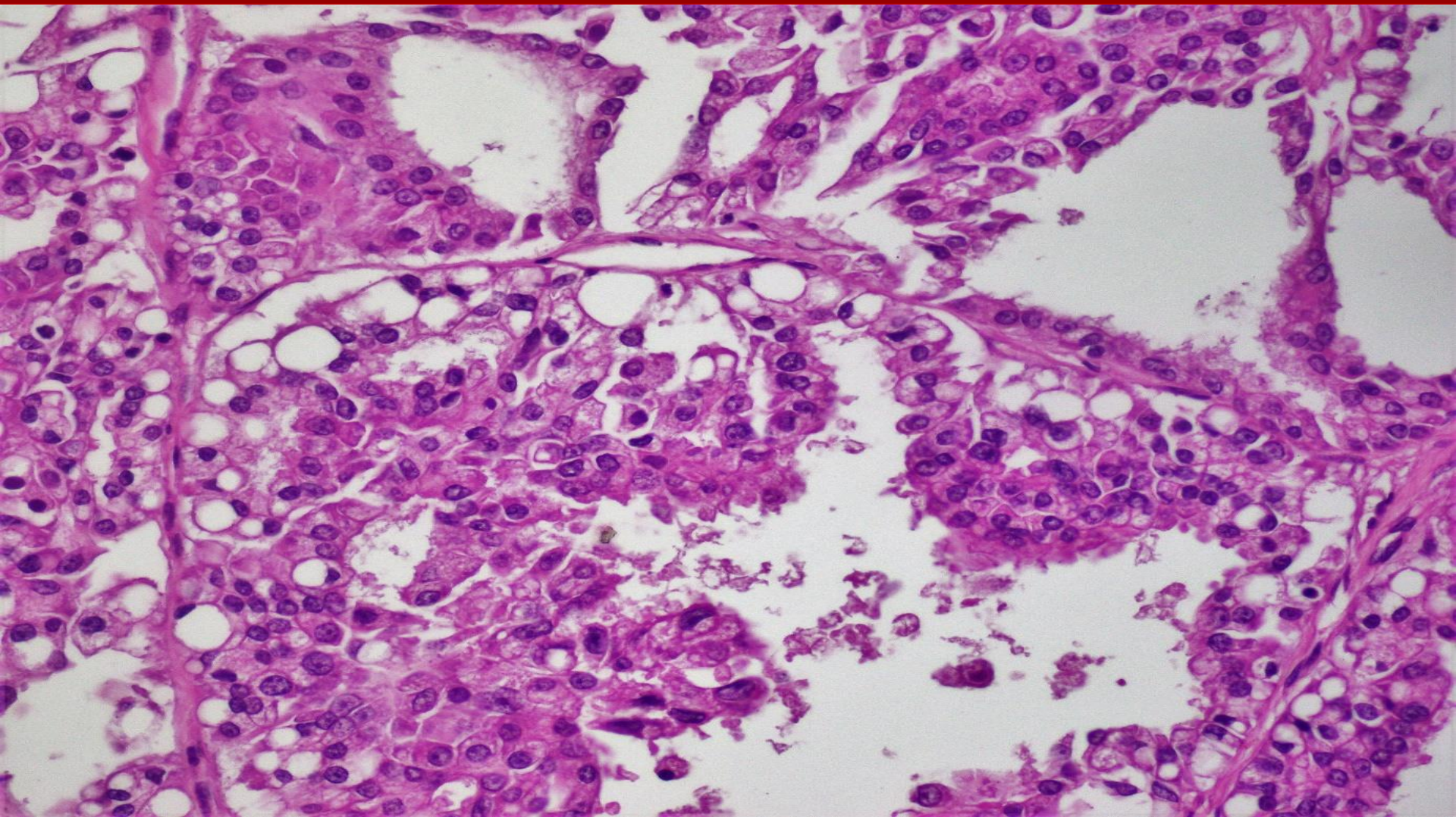


Secretory Carcinoma (MASC)

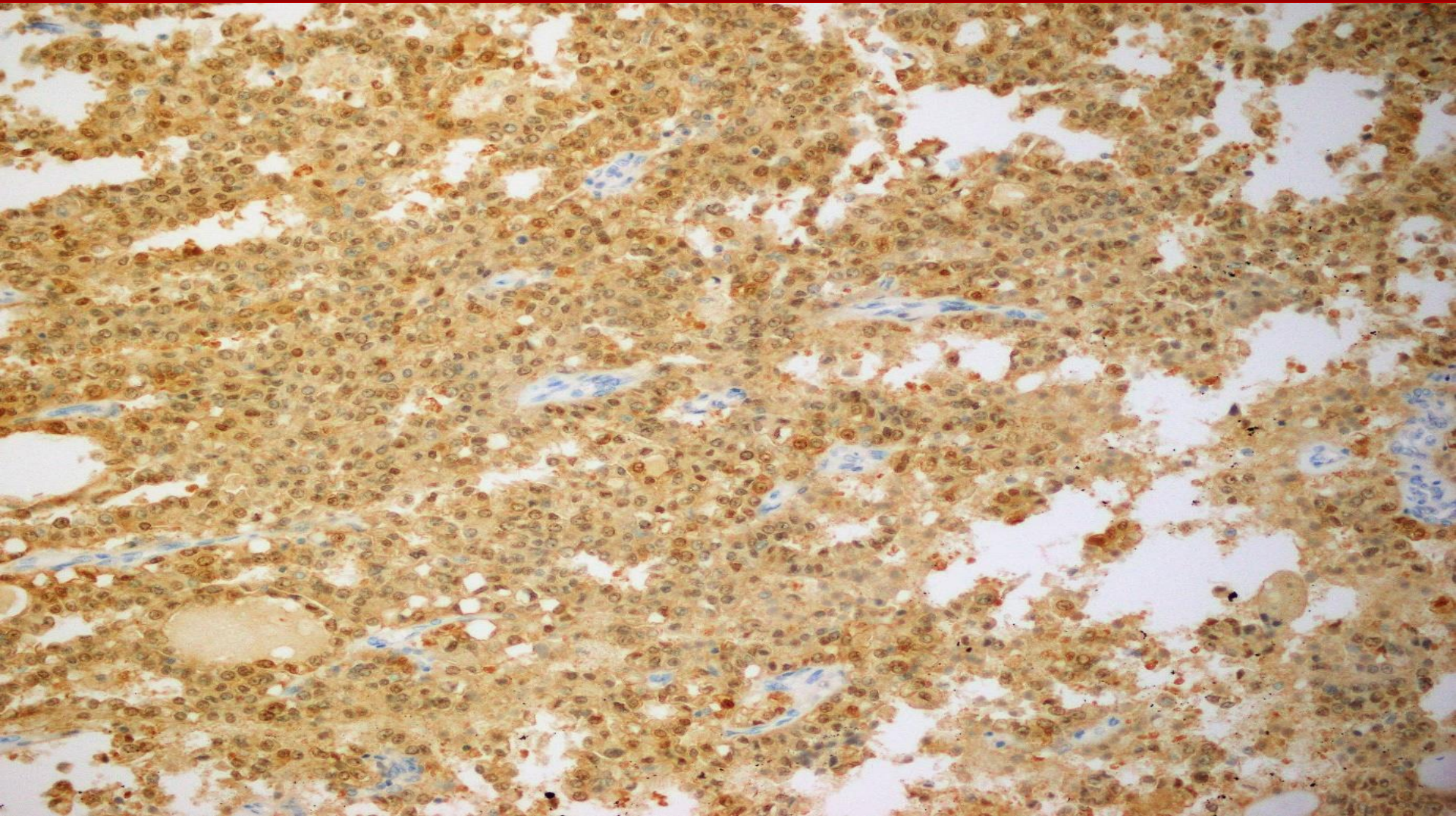




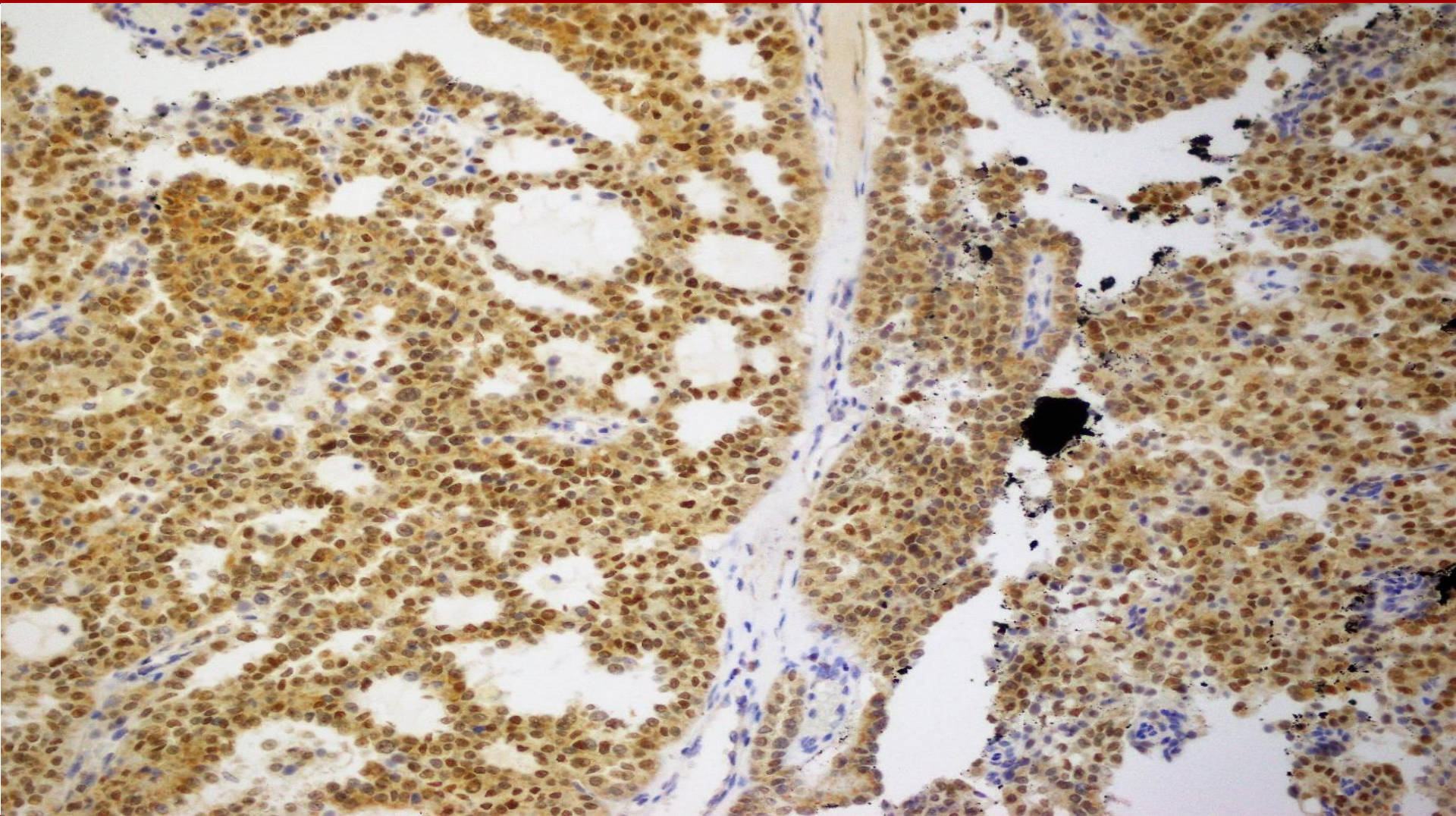




S100- diffuse cytoplasmic staining



GATA 3- strong nuclear staining



SECRETORY CARCINOMA OF SALIVARY GLAND



Microscopic Features

- Lobulated arrangement divided by fibrous septa with microcytic, tubular and solid arrangement.
- Abundant secretions in microcytic and tubular cystic spaces
 - SC with prominent fibrosclerotic stroma with isolated tumor cells in small islands or trabeculae seen mostly in the central part of the tumor.
 - SC with predominant single large cyst, apocrine-like epithelial lining



Clinical Features

- Adults, Mean age 47 years (range:14 to 78 years)
- Slightly more common in males
- Parotid gland most commonly involved followed by oral cavity and submandibular gland



Differential diagnoses (Major)

- Acinic cell carcinoma (ACC)
- Intraductal carcinoma
- Low grade mucoepidermoid carcinoma

Less common

- Polymorphous adenocarcinoma (PLGA),
- Low-grade adenocarcinoma or cystadenocarcinoma NOS, and
- Cystadenoma NOS



Three important points to differentiate **ACC** VS **Secretory Carcinoma**

- i. SC shows **no basophilic granularity** in cytoplasm (Hallmark of ACC)
- ii. SC strongly expresses **S100** and **Mammoglobin/GATA3/GCDFP15** and are negative for **DOG1** (ACC shows opposite profile)
- iii. Specific molecular alteration (t12;15-ETV6-NTRK3)



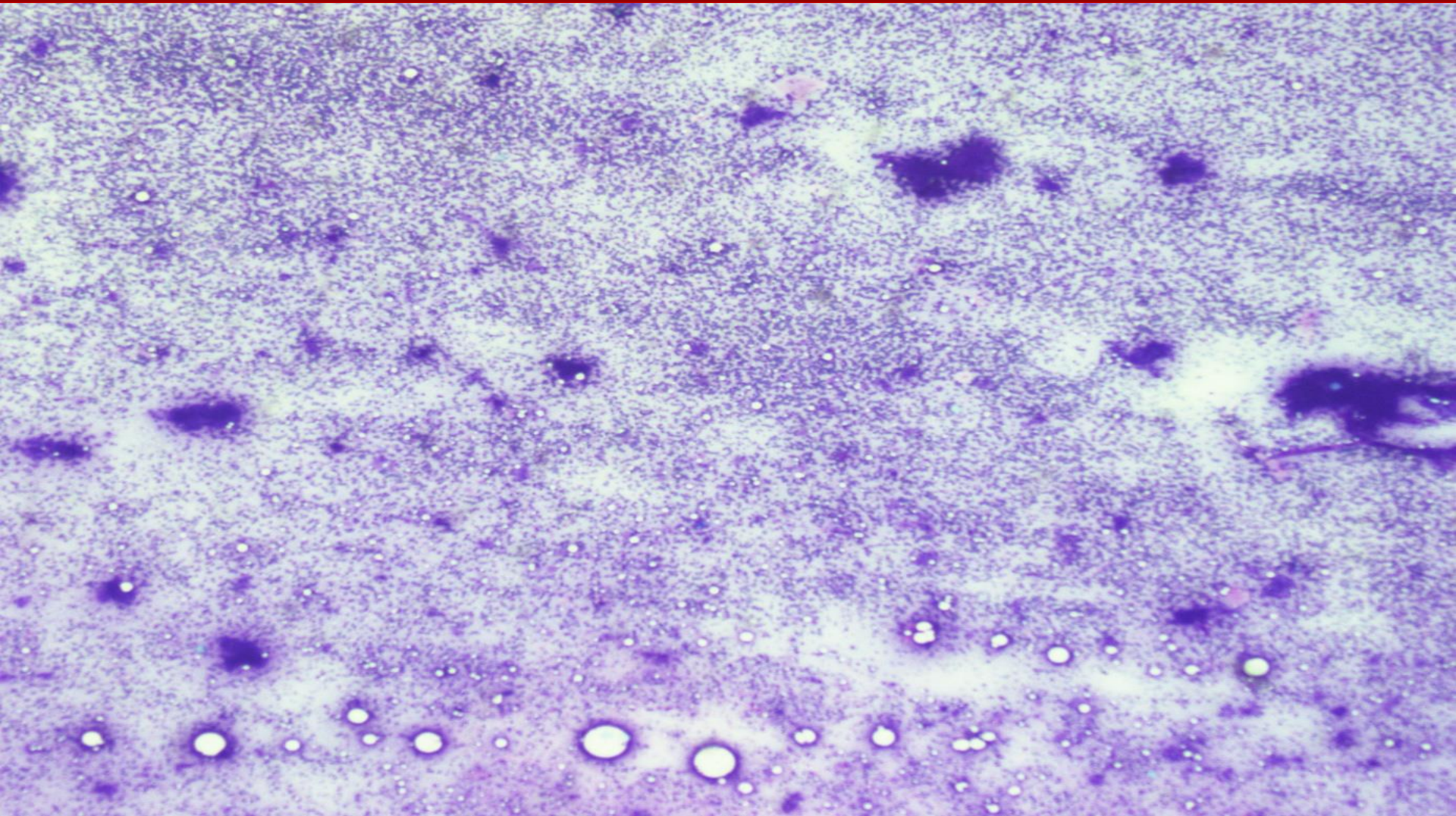
CASE NO 3

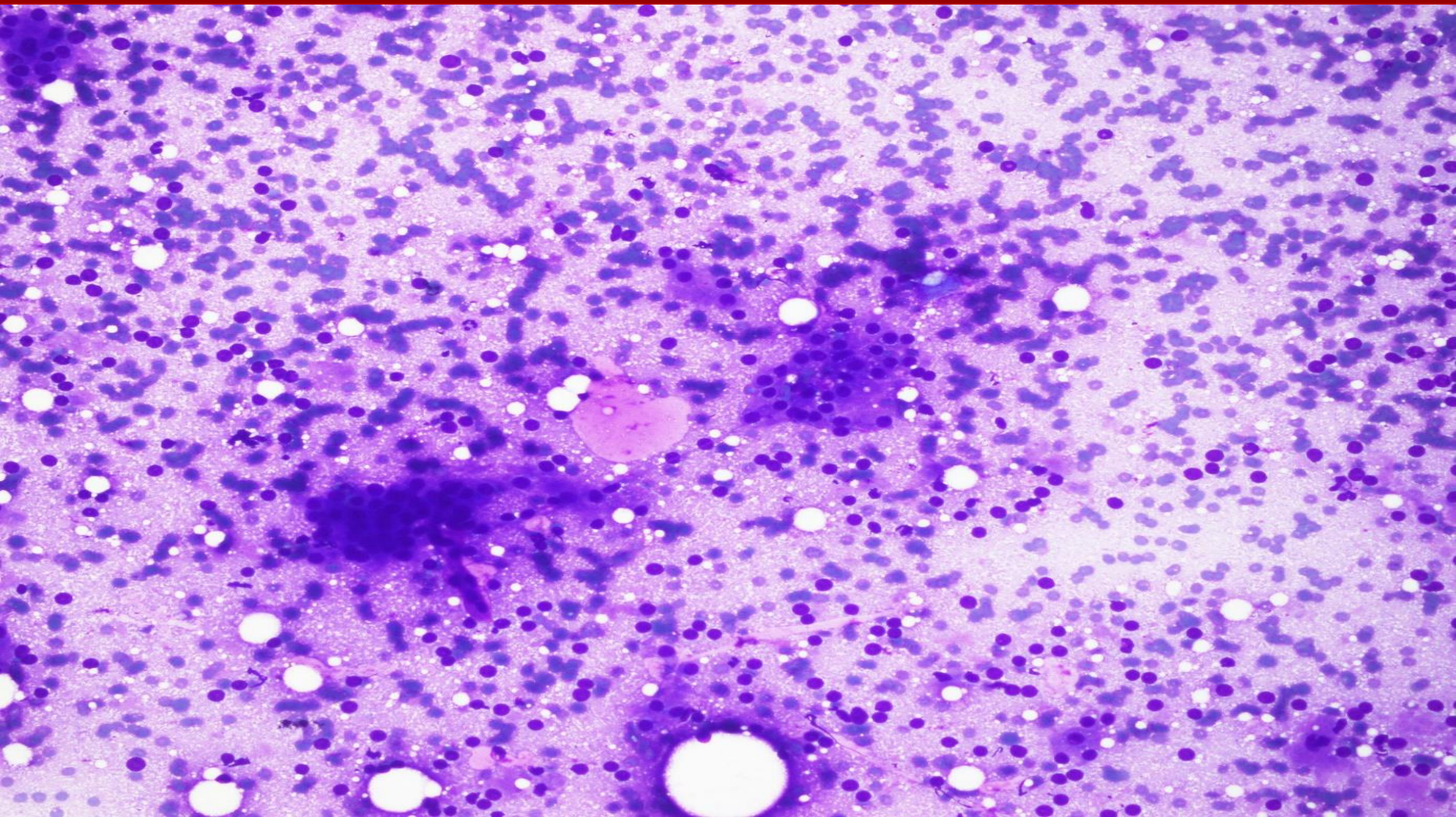
50 female

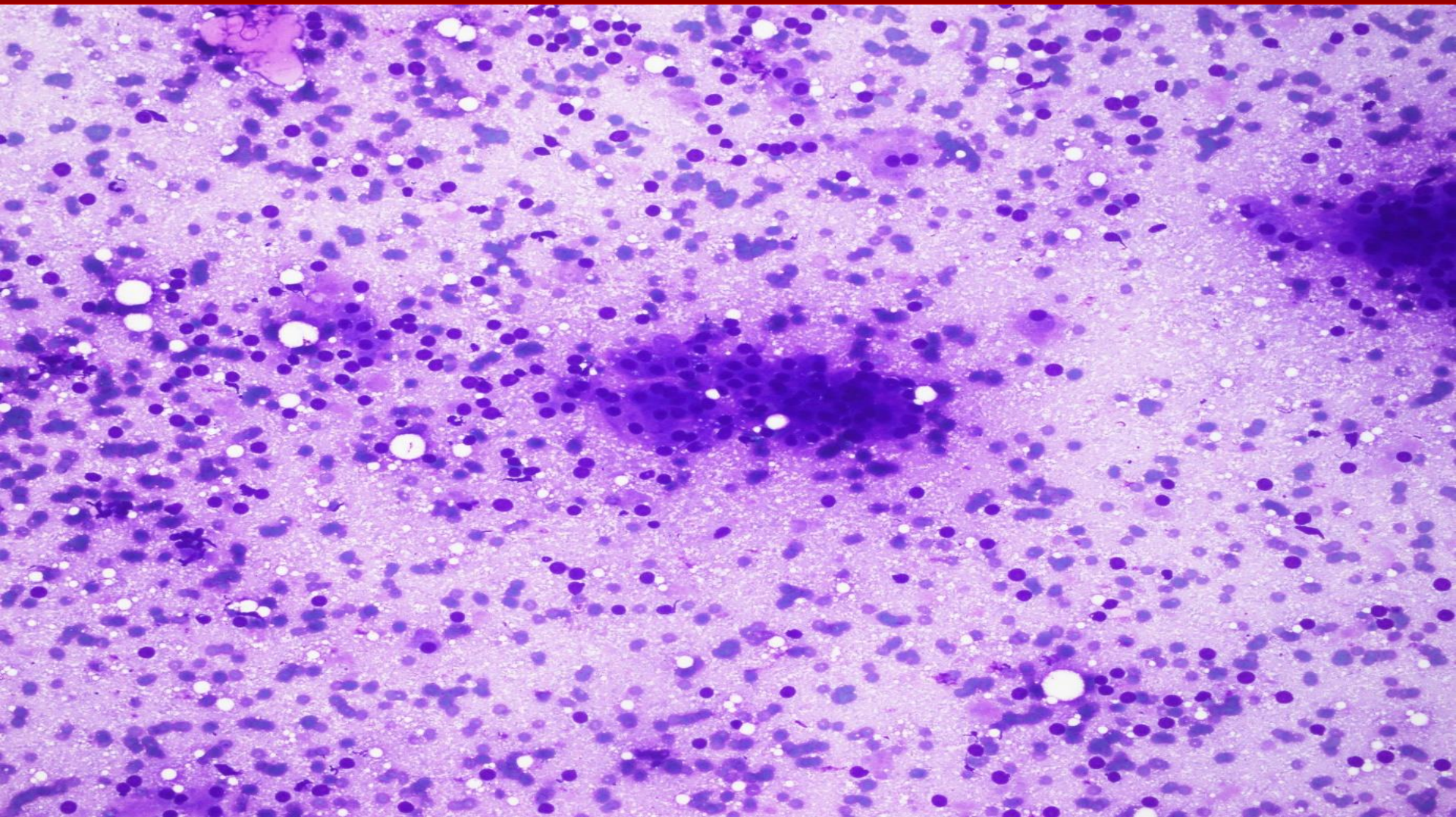
Parotid gland swelling

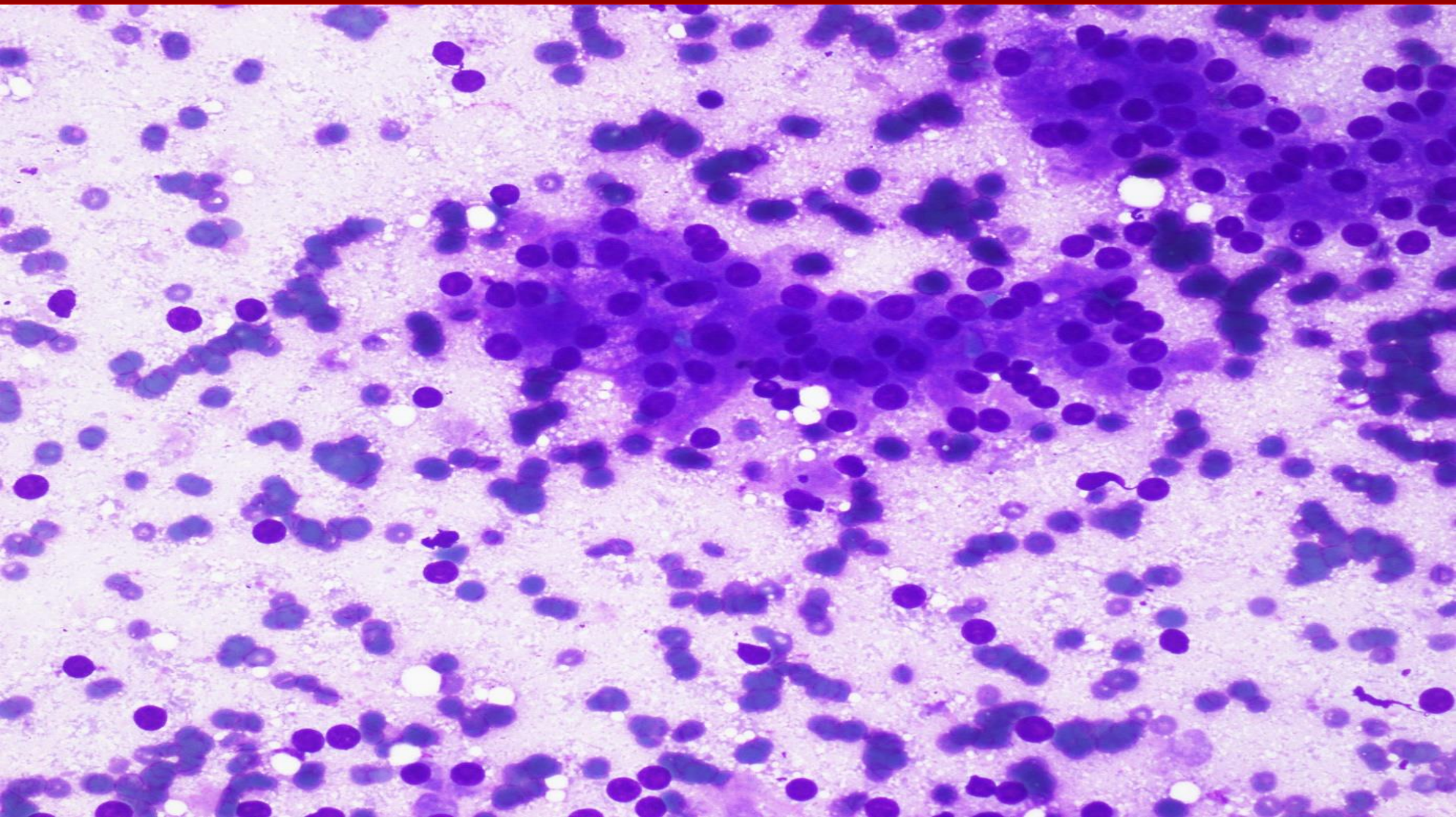
FNA

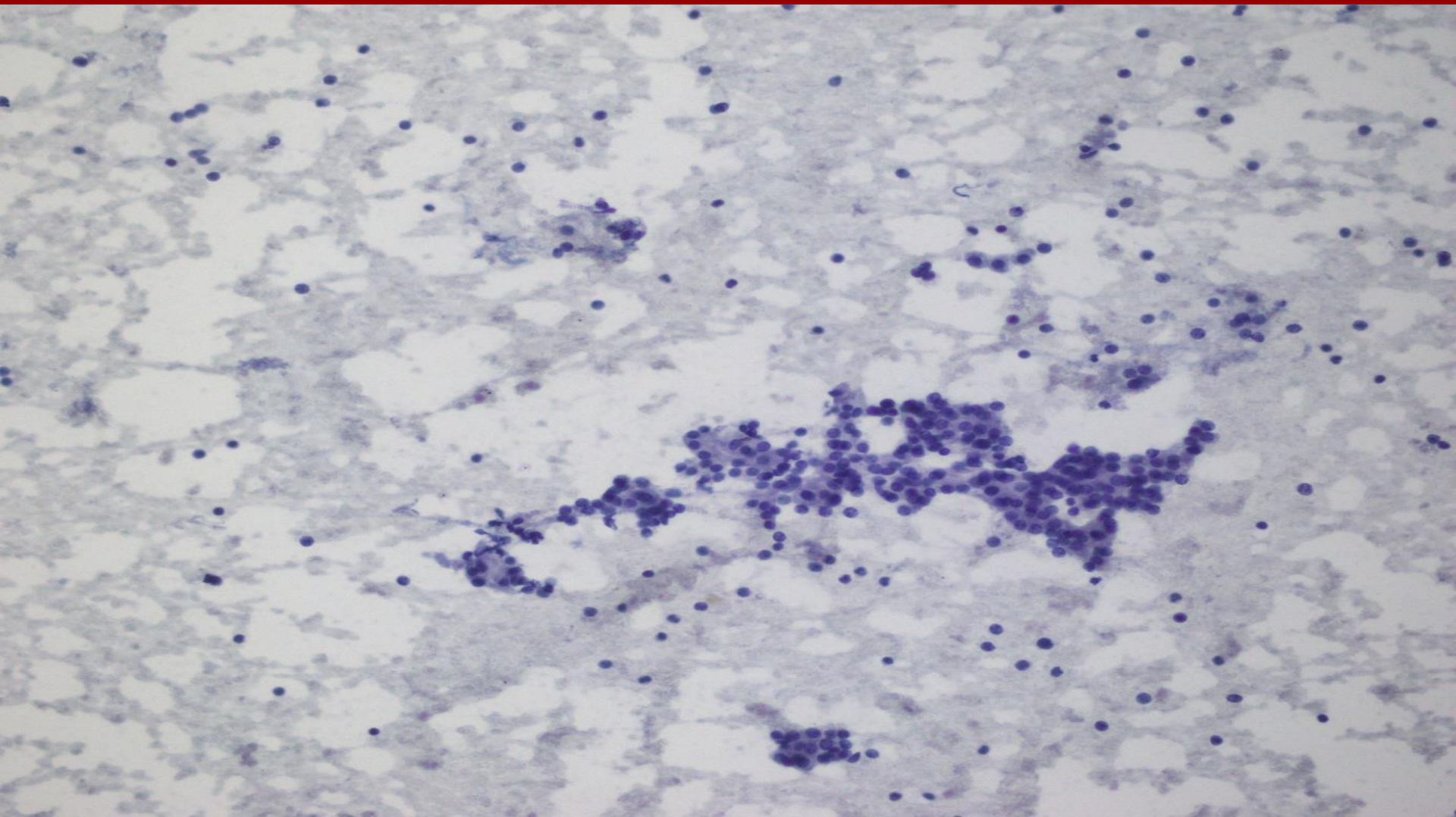


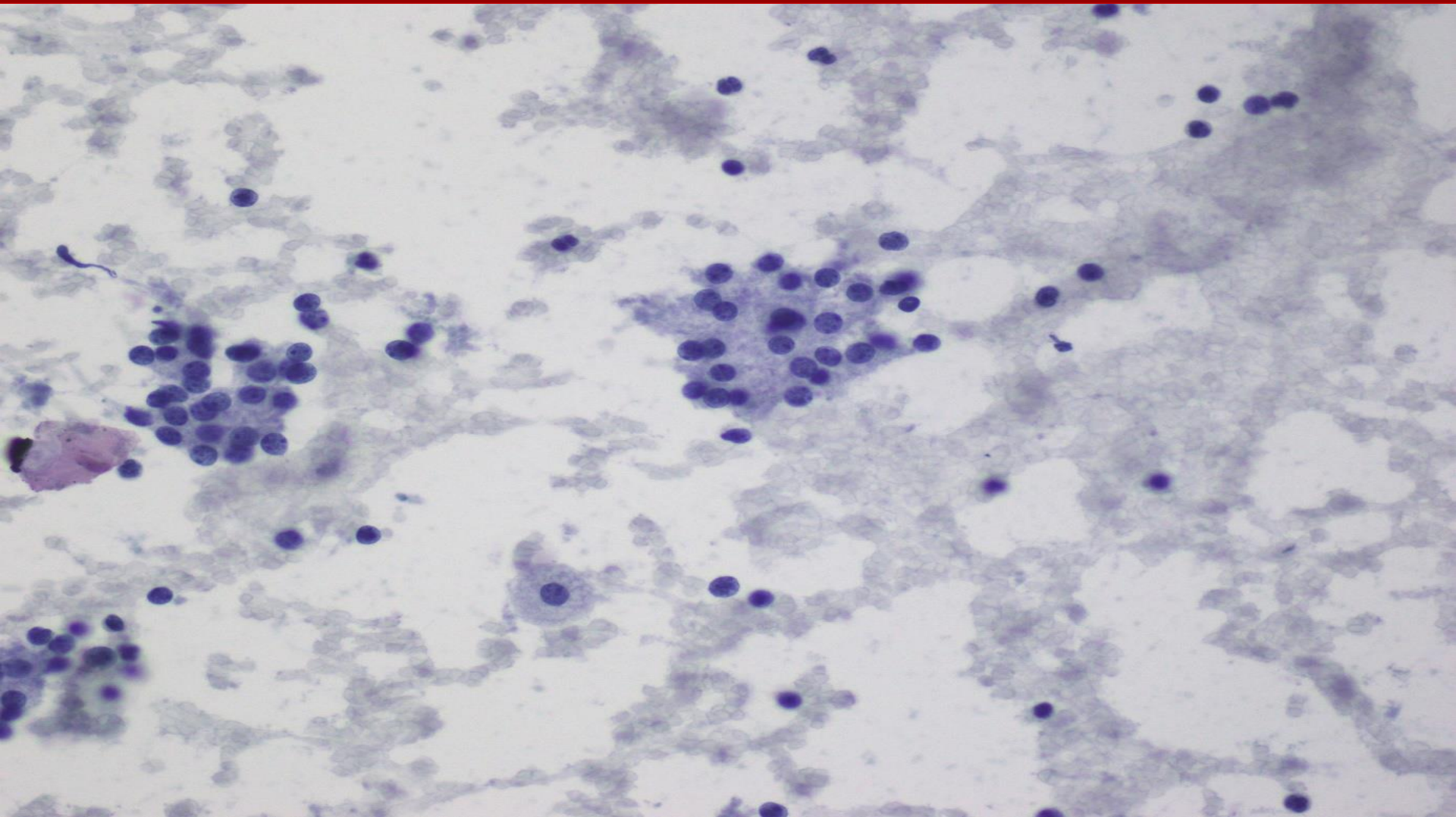


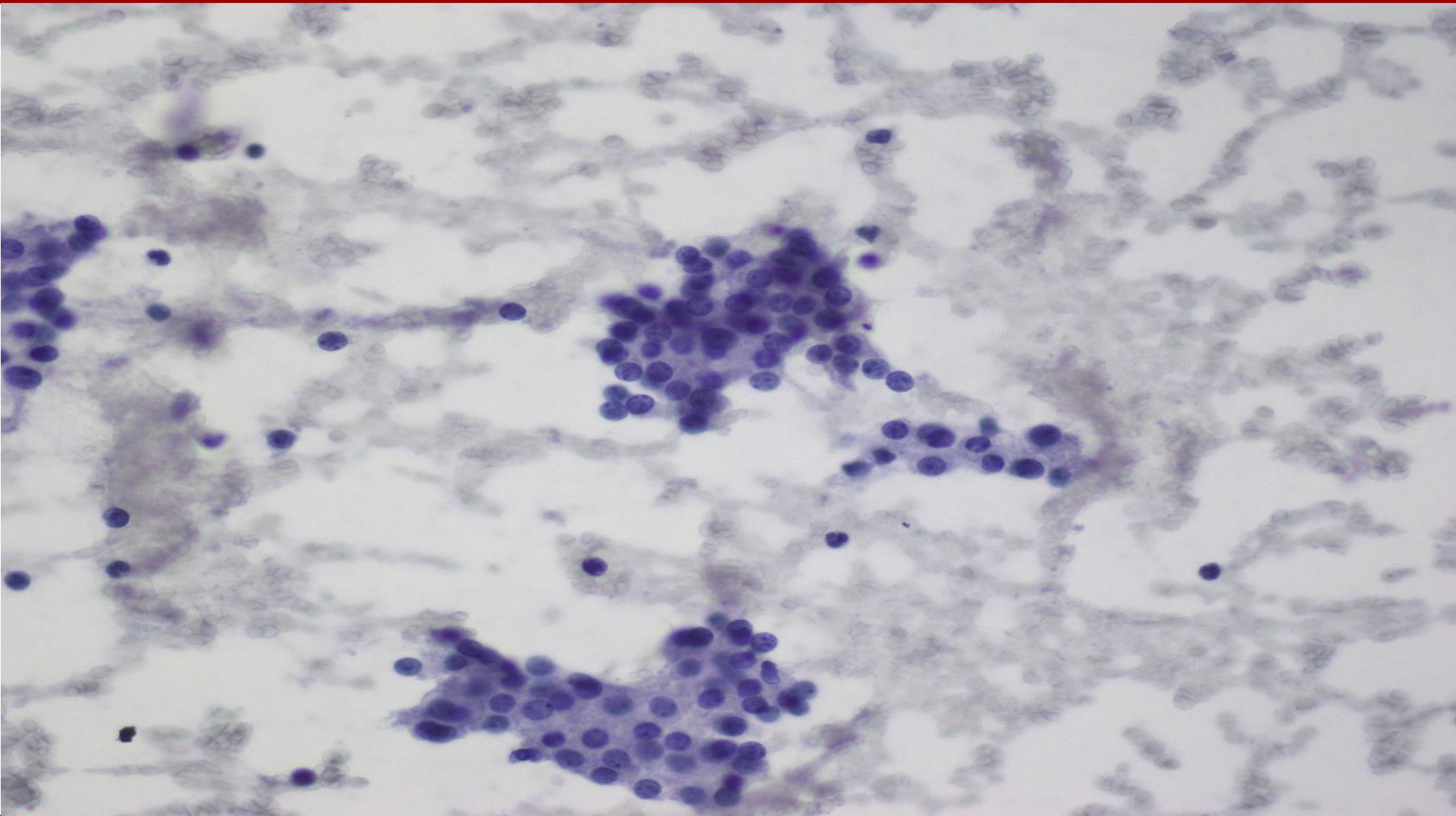


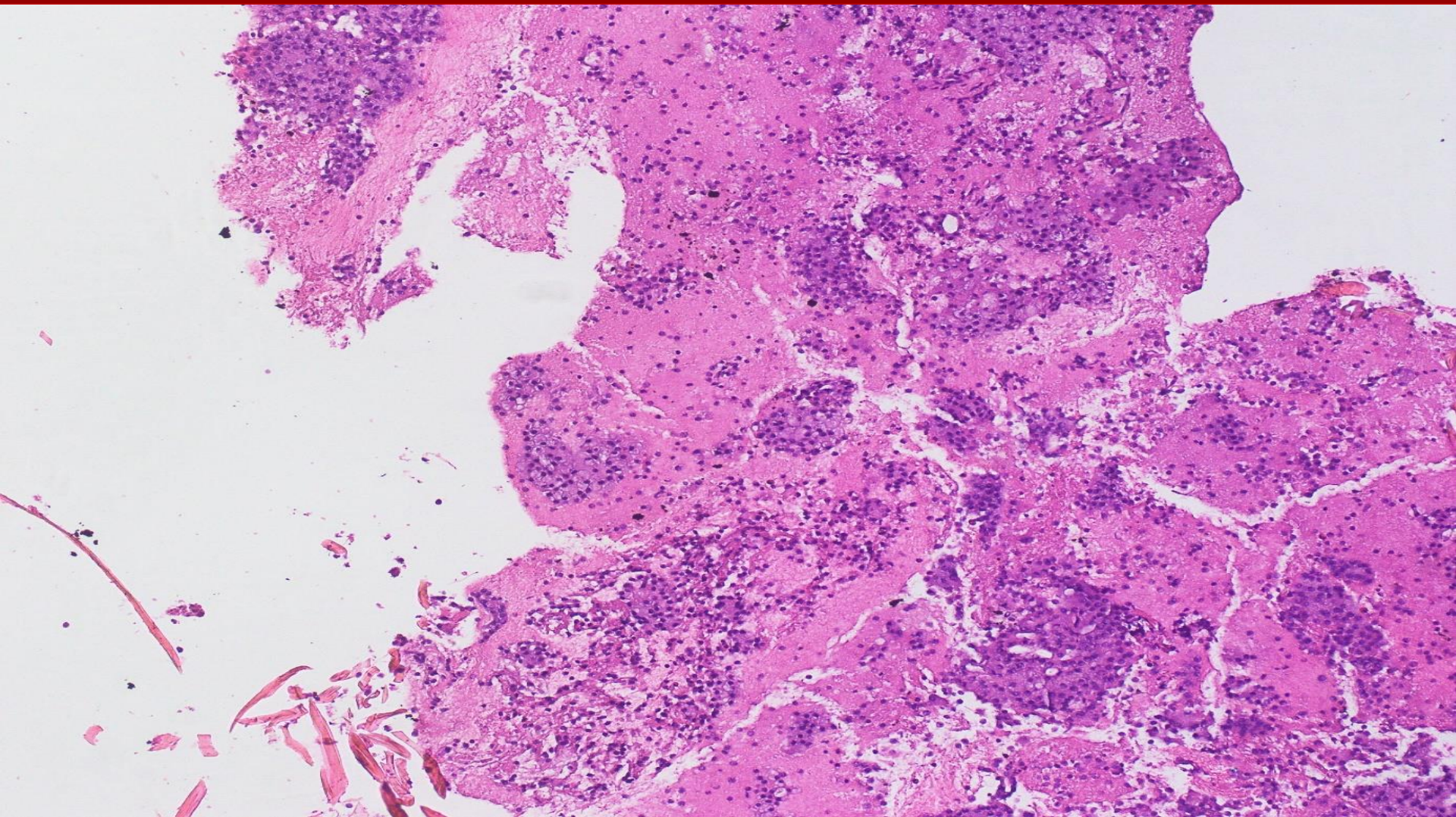


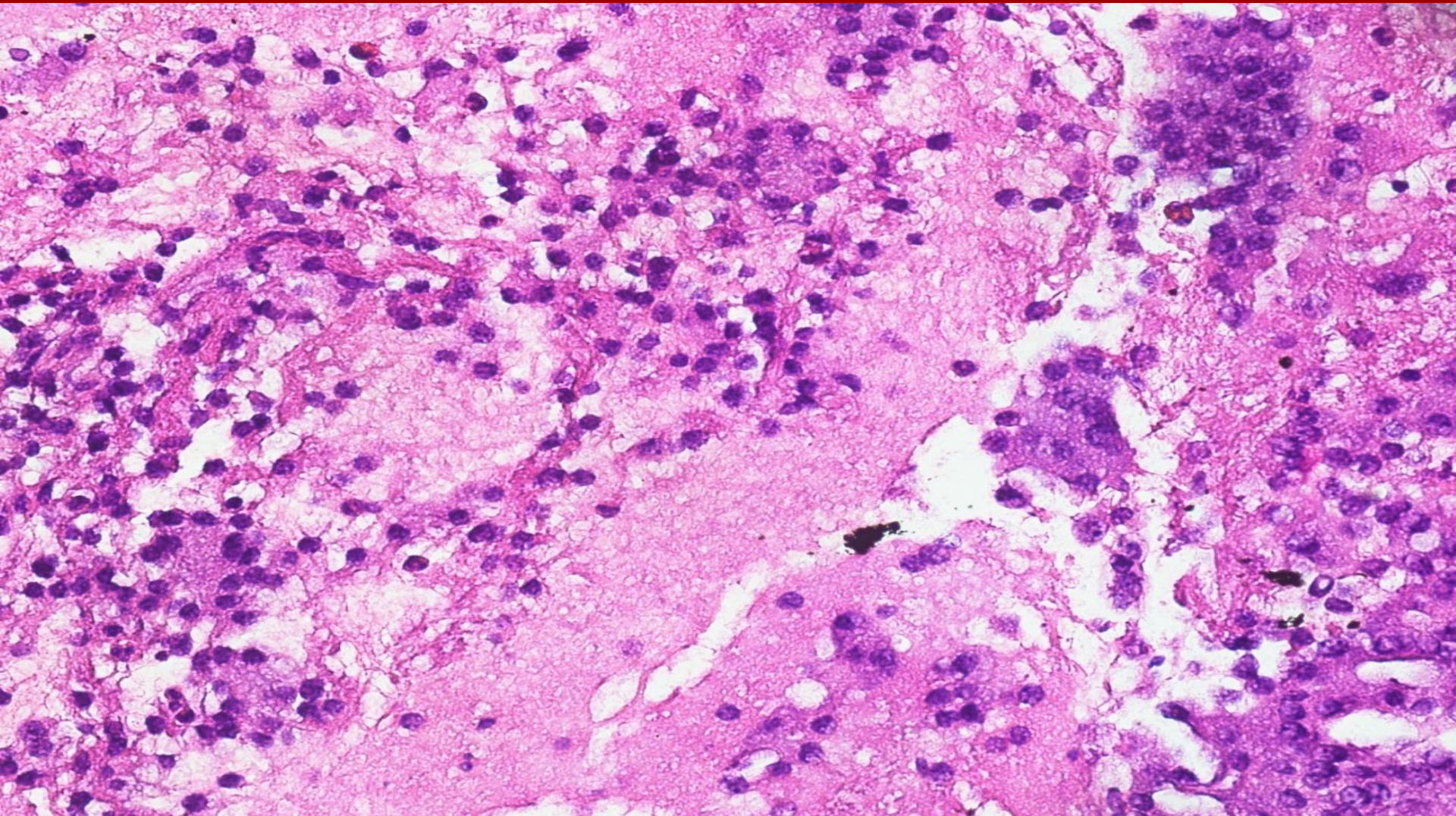


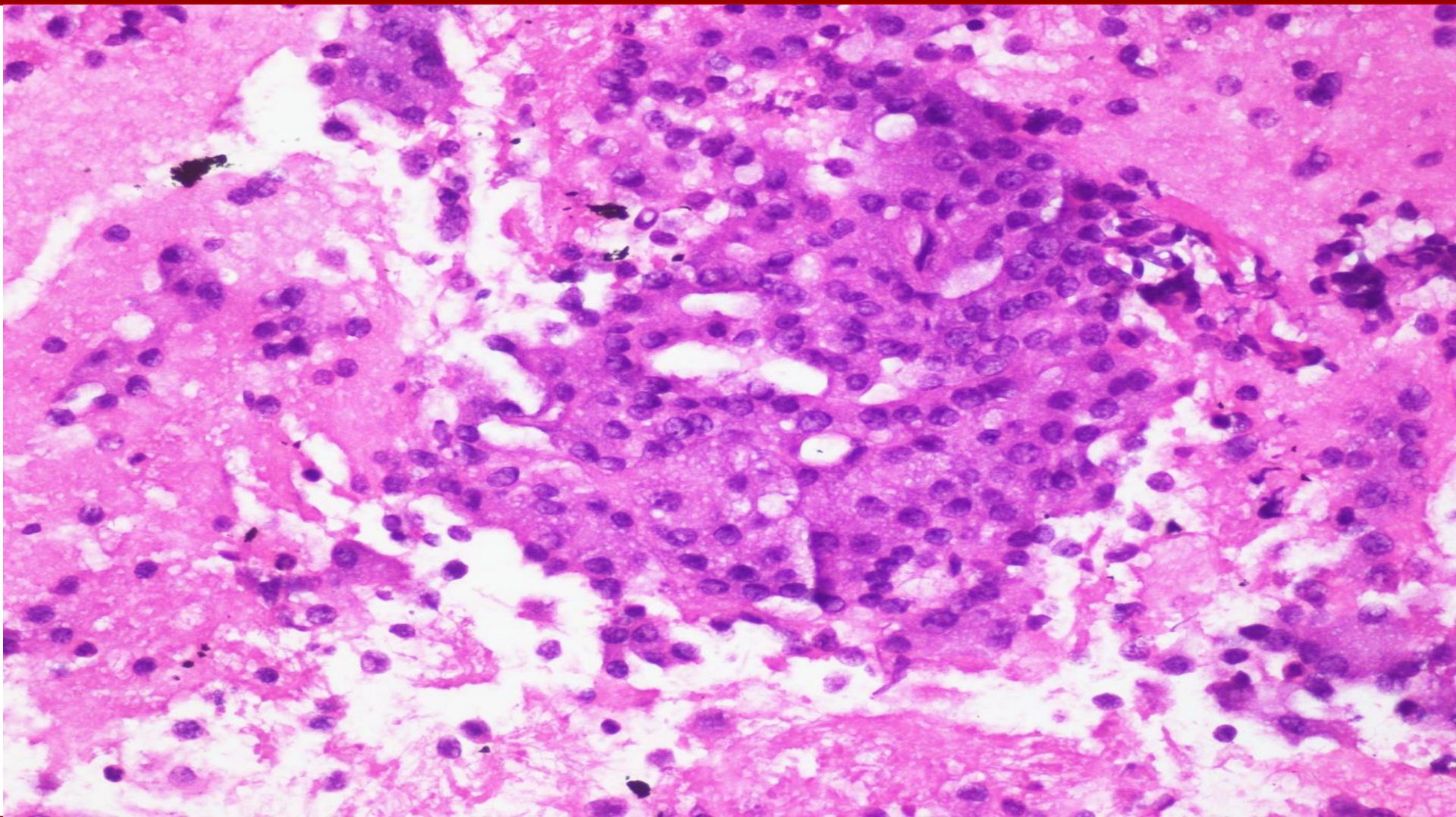










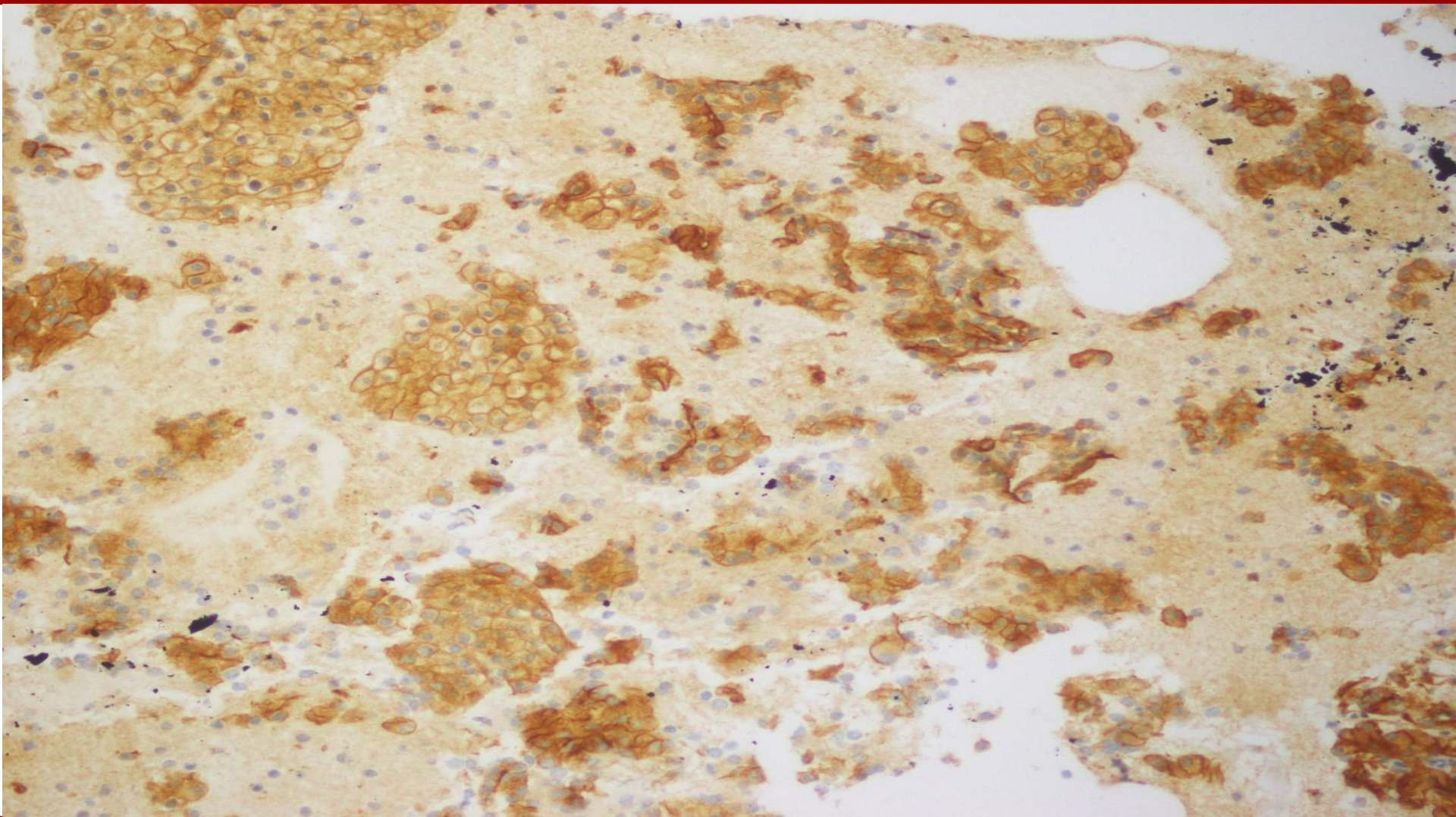


Differentials

- Normal salivary gland
- Sialadenosis
- Oncocytoma
- Acinic cell carcinoma
- Warthin's tumor
- Mucoepidermoid carcinoma
- Secretory carcinoma of salivary gland(MASC)

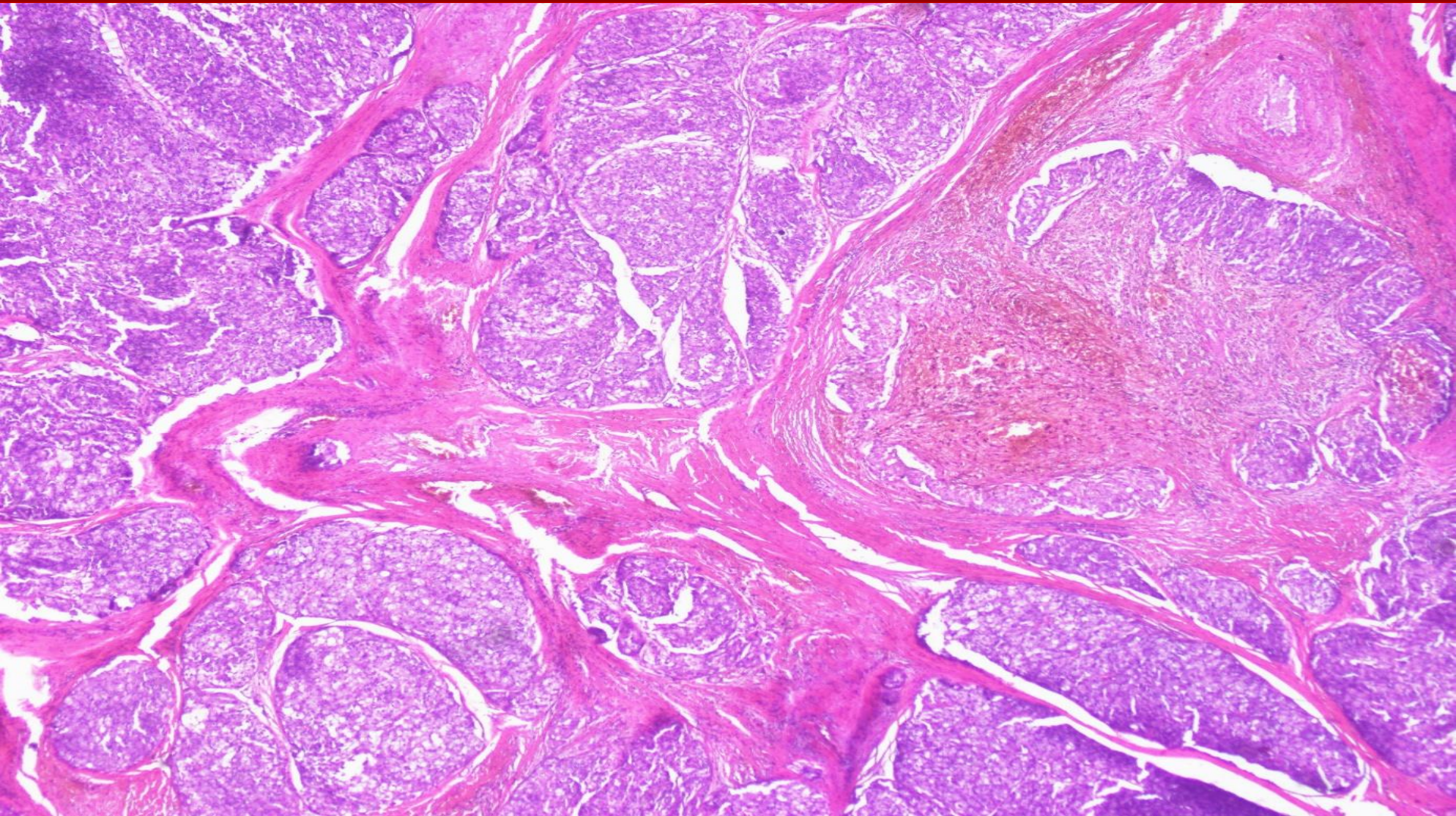


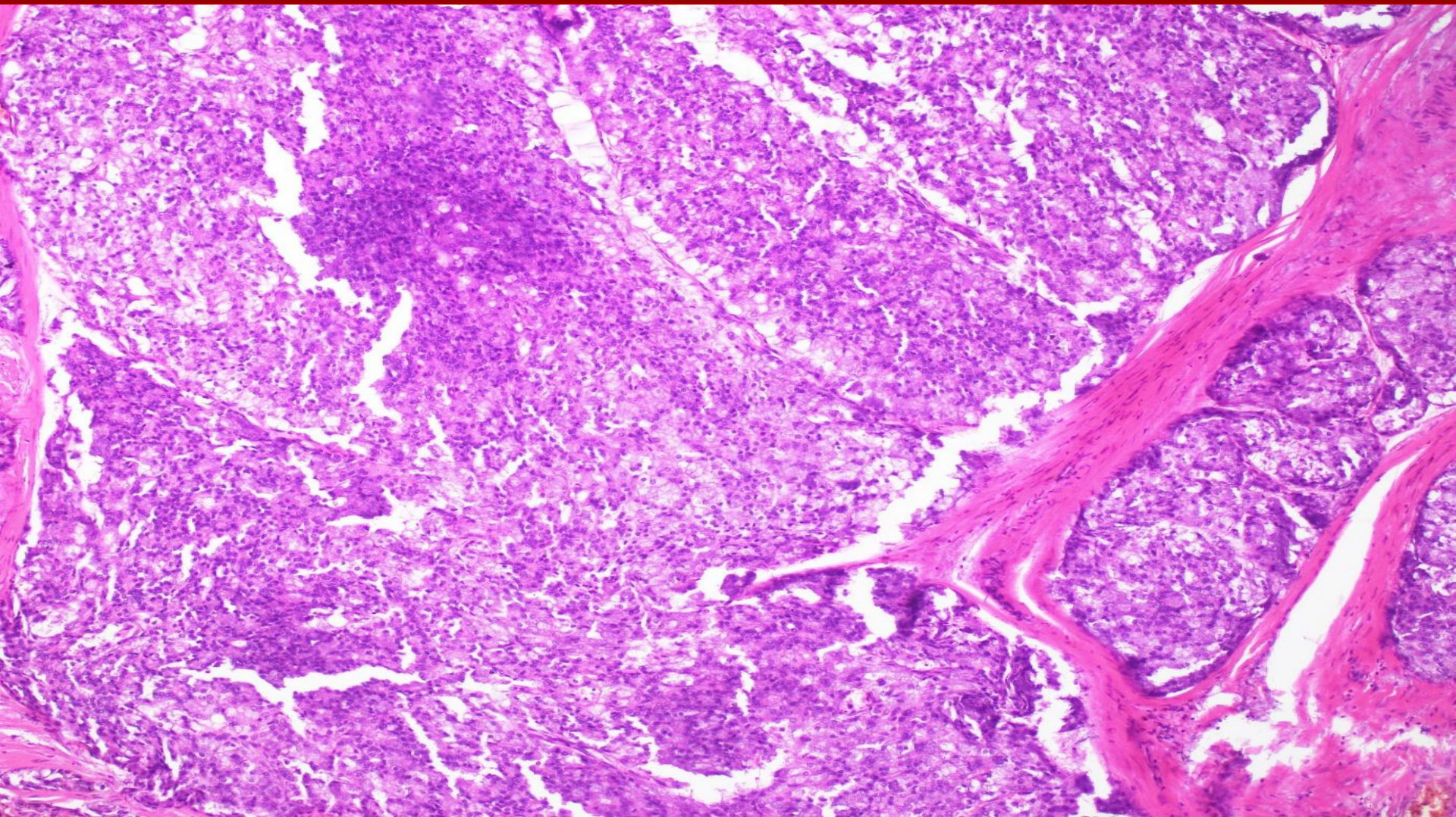
DOG 1

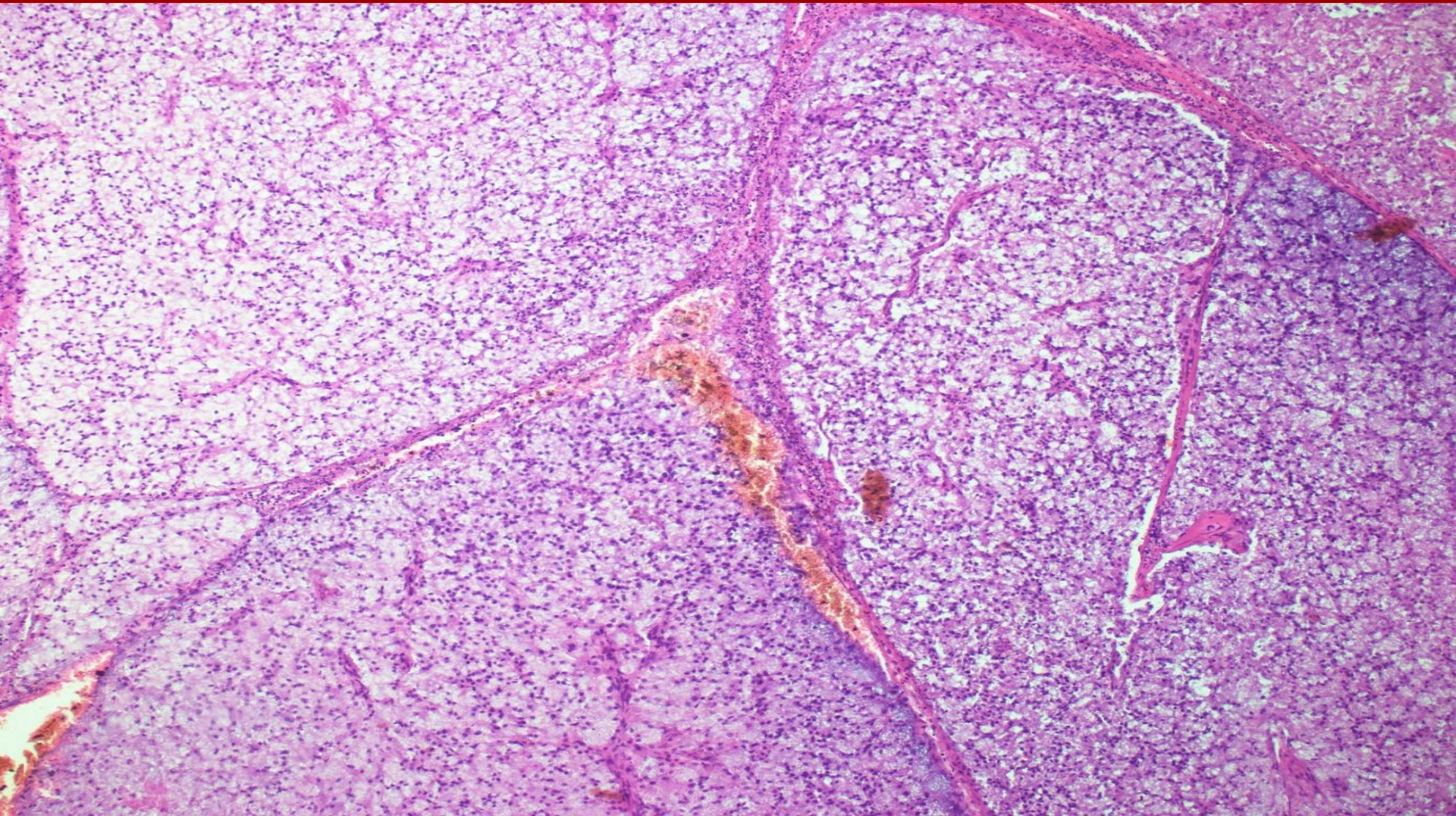


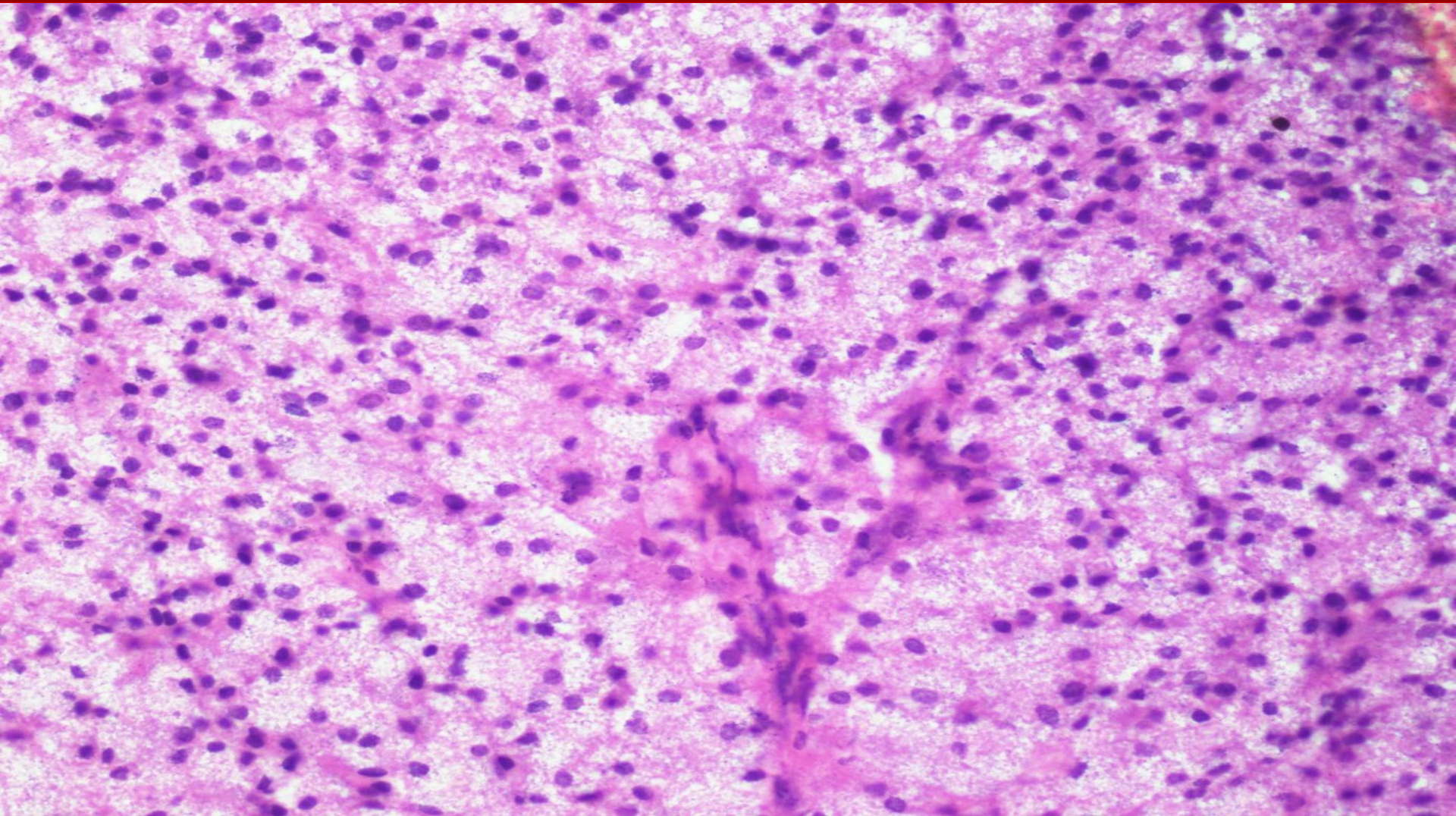
Acinic Cell Carcinoma











ACINIC CELL CARCINOMA



Cytological Features

- Cellular smear
- Sheets, crowded clusters, isolated cells
- Large polygonal serous-type cells
- PAS-positive diastase-resistant cytoplasmic zymogen granules
- Indistinct cell borders
- Bland round nuclei
- Background shows naked nuclei with or without lymphocytes



Histological Features

- Cell types
 - a) Acinar cells
 - b) Clear or vacuolated cells
 - c) Intercalated duct-like cells
 - d) Non-specific glandular cells



■ Histological patterns

a) Solid

b) Follicular

c) Microcystic

d) Papillary cystic



Immunohistochemistry

- **Keratin**
- **alpha-1-antichymotrypsin**
- **alpha amylase**
- **DOG 1**
- **SOX 10**
- **myoepithelial markers**
- **PAS+ diastase resistant (granules)**

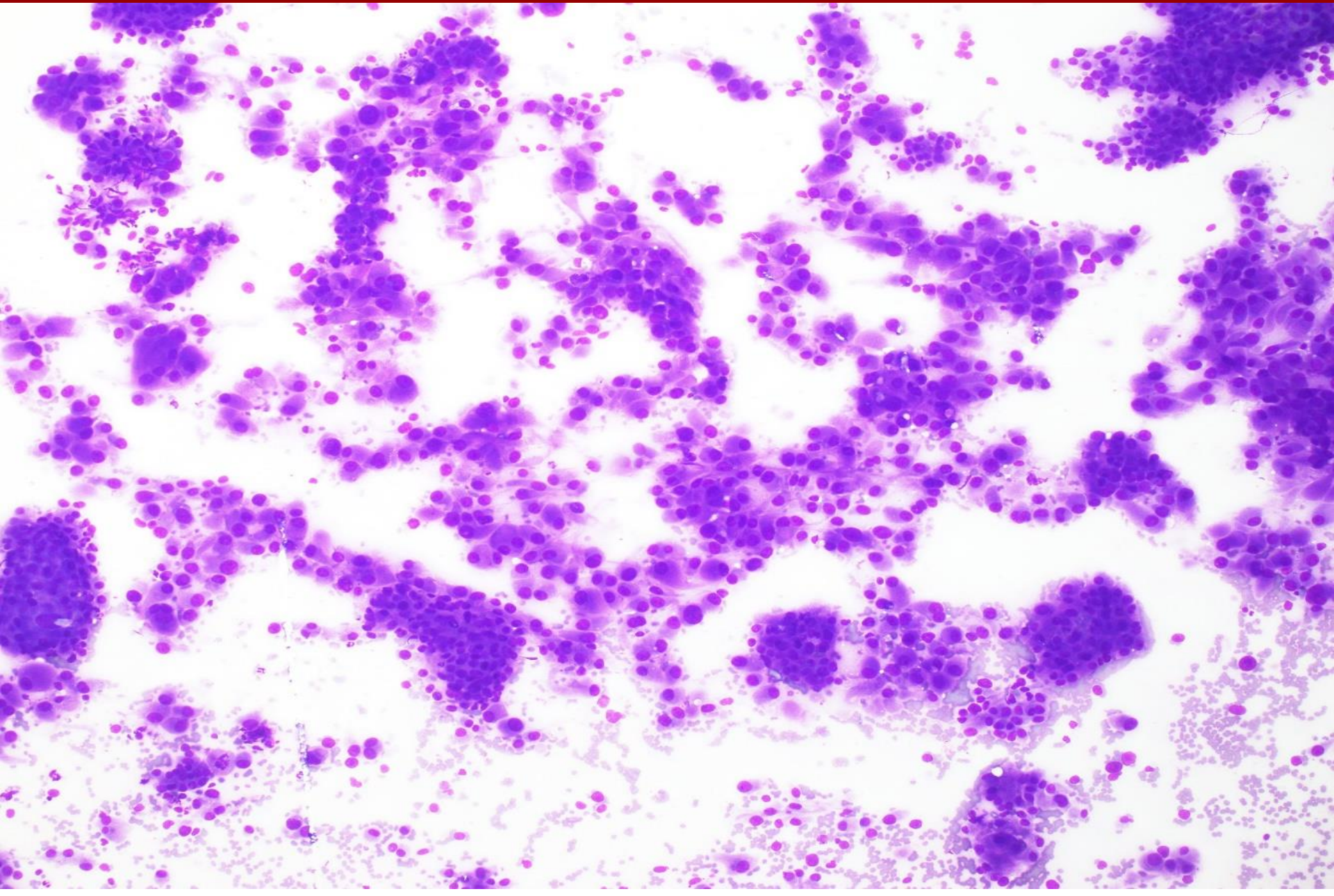


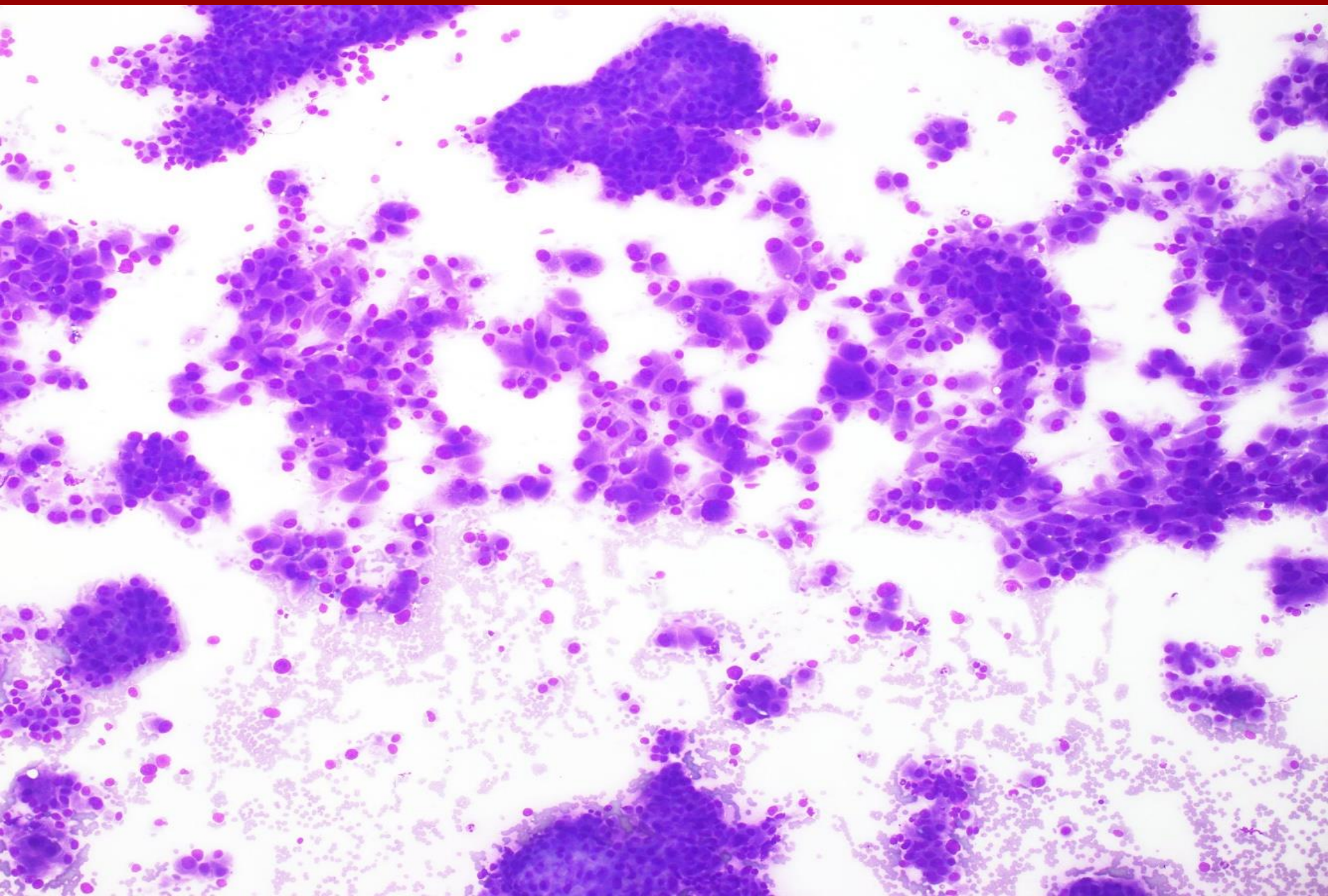
Case no. 4

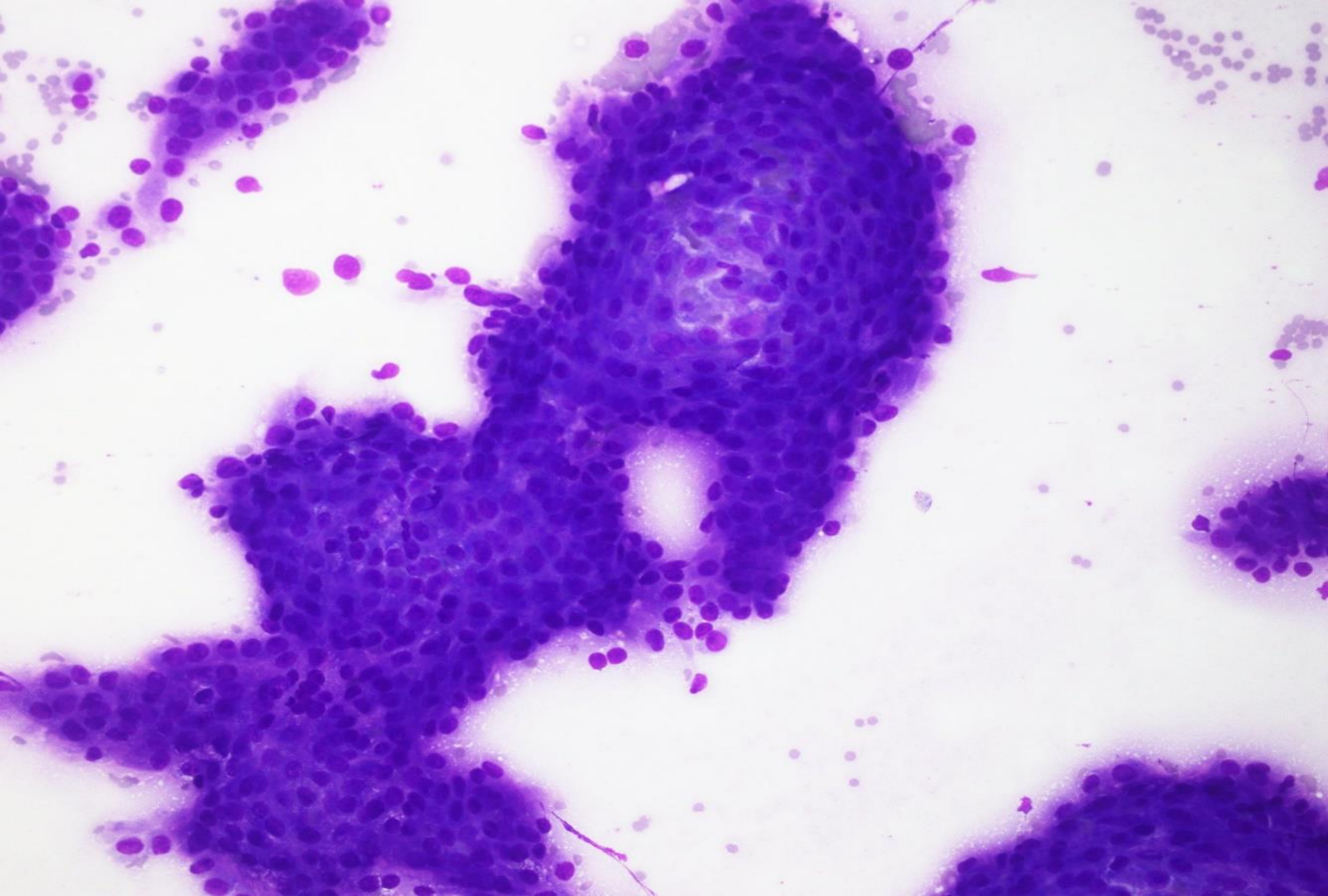
32 male

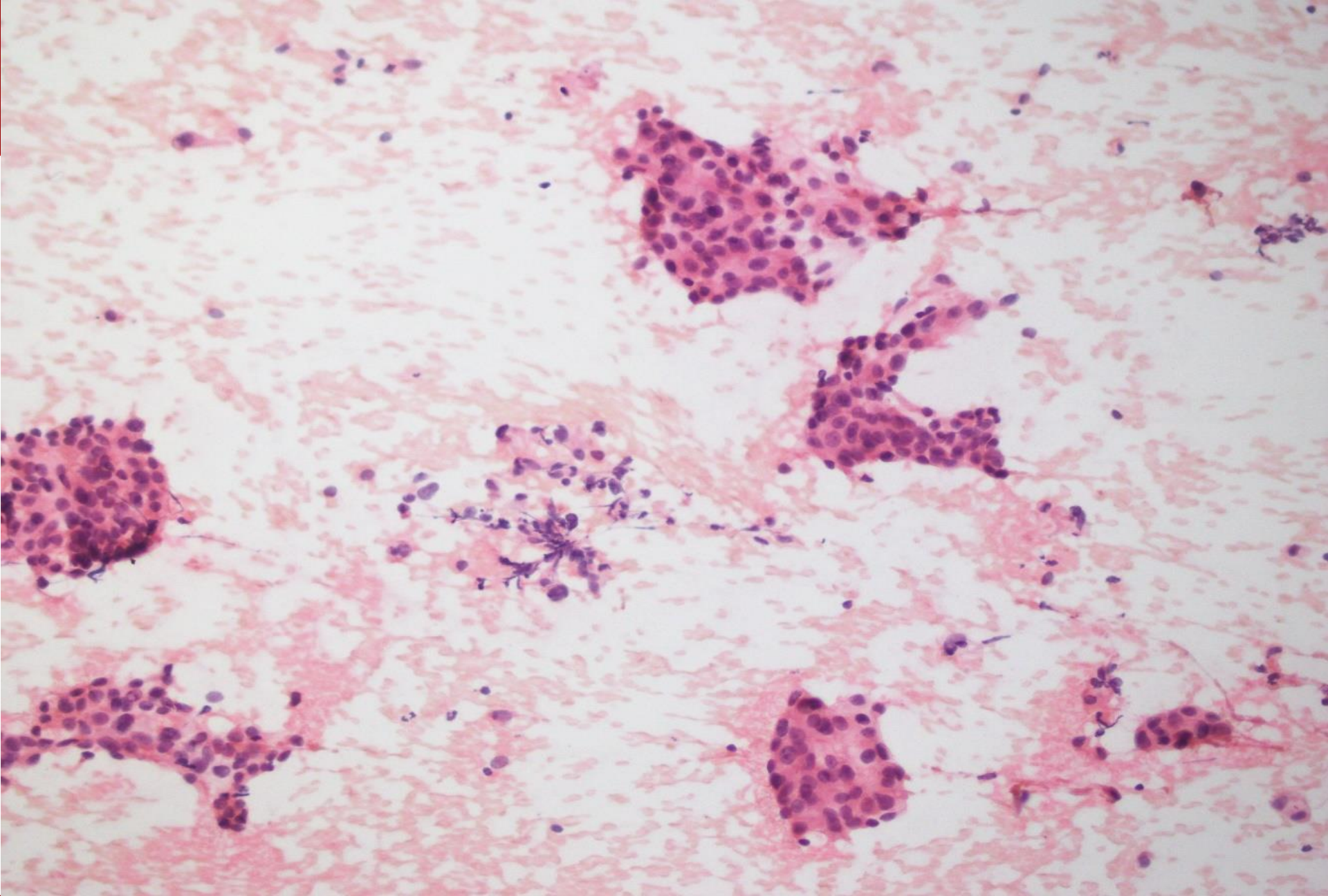
Parotid gland swelling

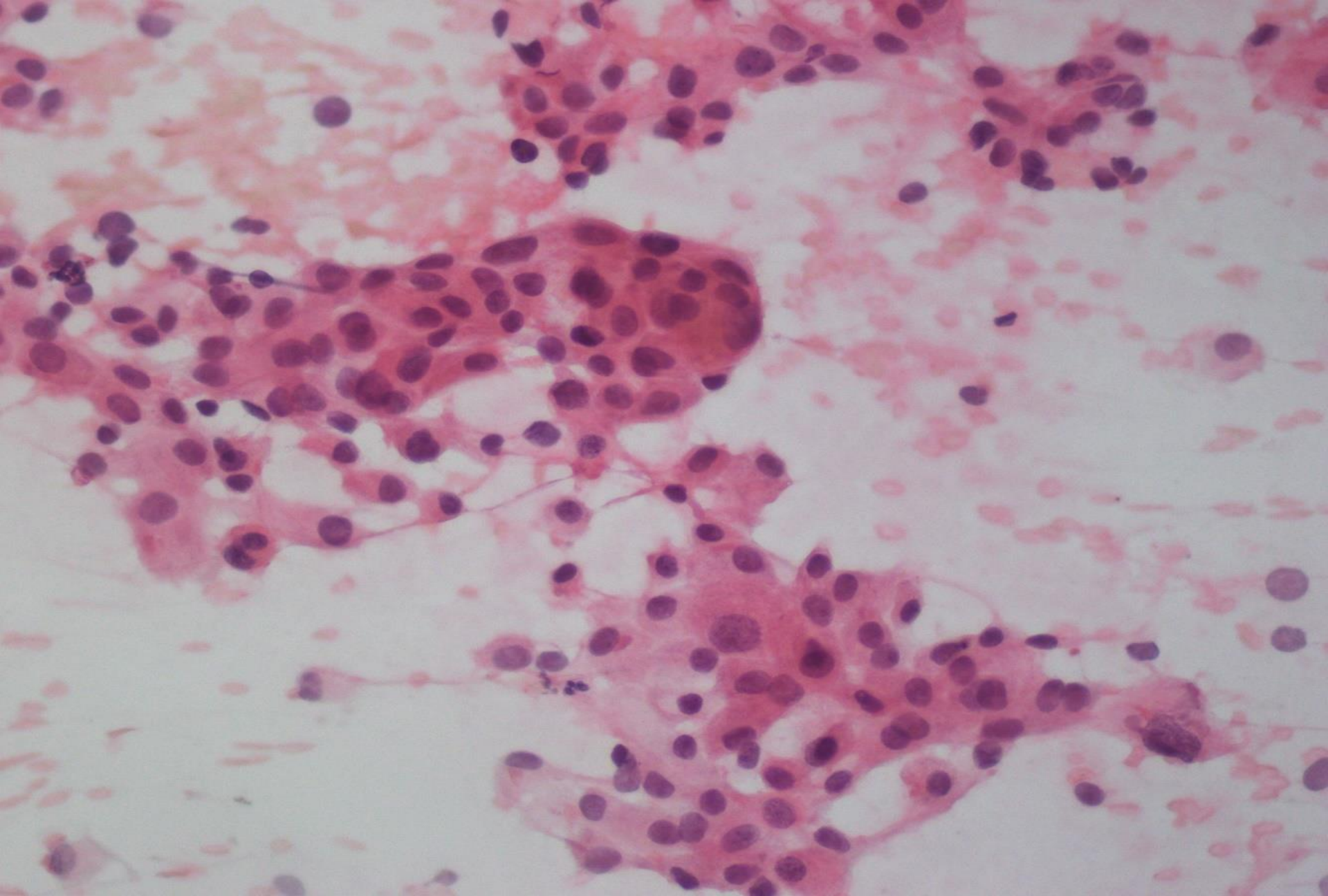


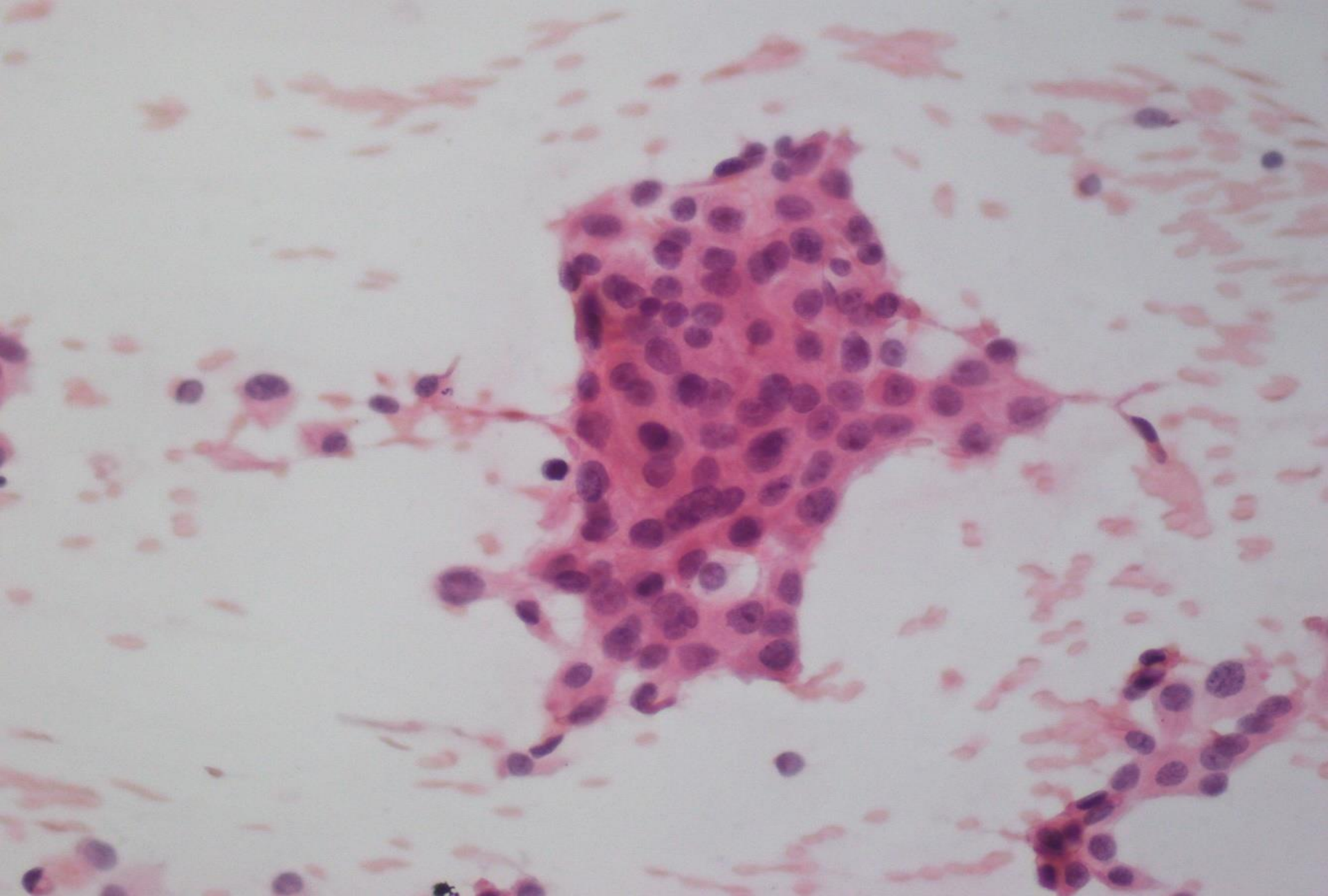










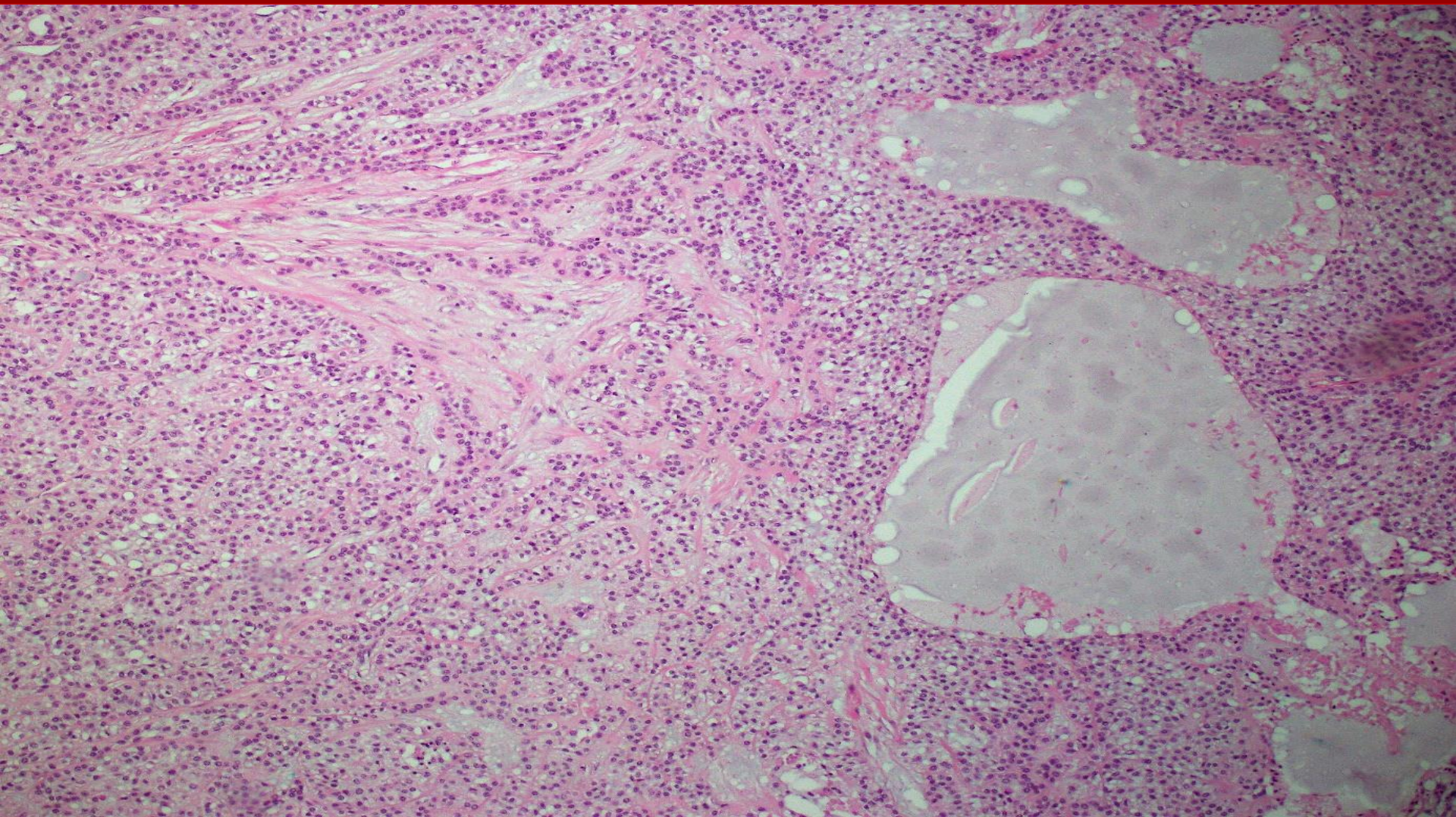


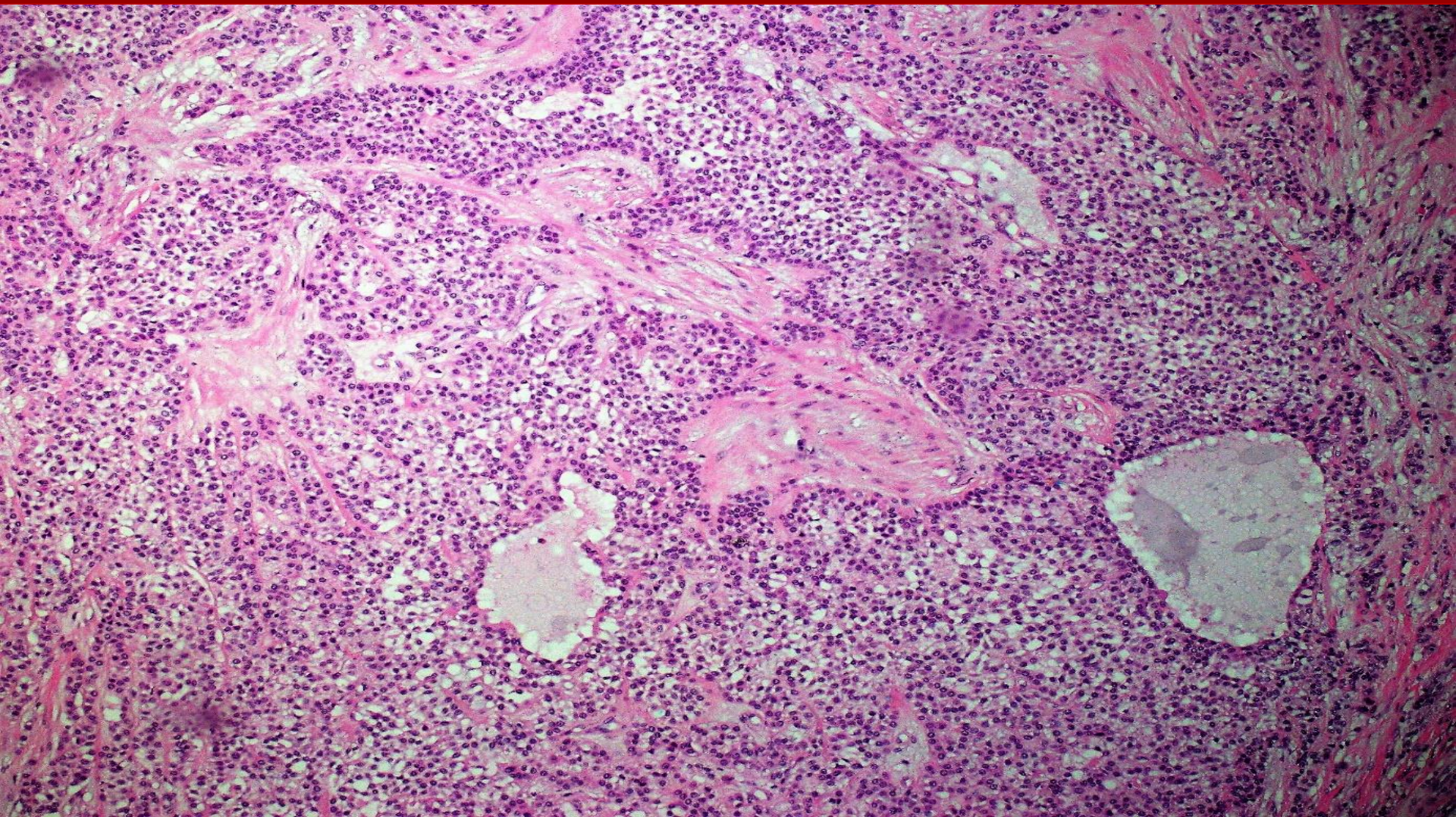
- Acquired cyst (mucocele or retention cyst)
- Chronic sialadenitis with mucinous metaplasia of ducts
- Warthin's tumor
- Pleomorphic adenoma
- Secretory carcinoma of salivary gland (MASC)
- Mucoepidermoid carcinoma

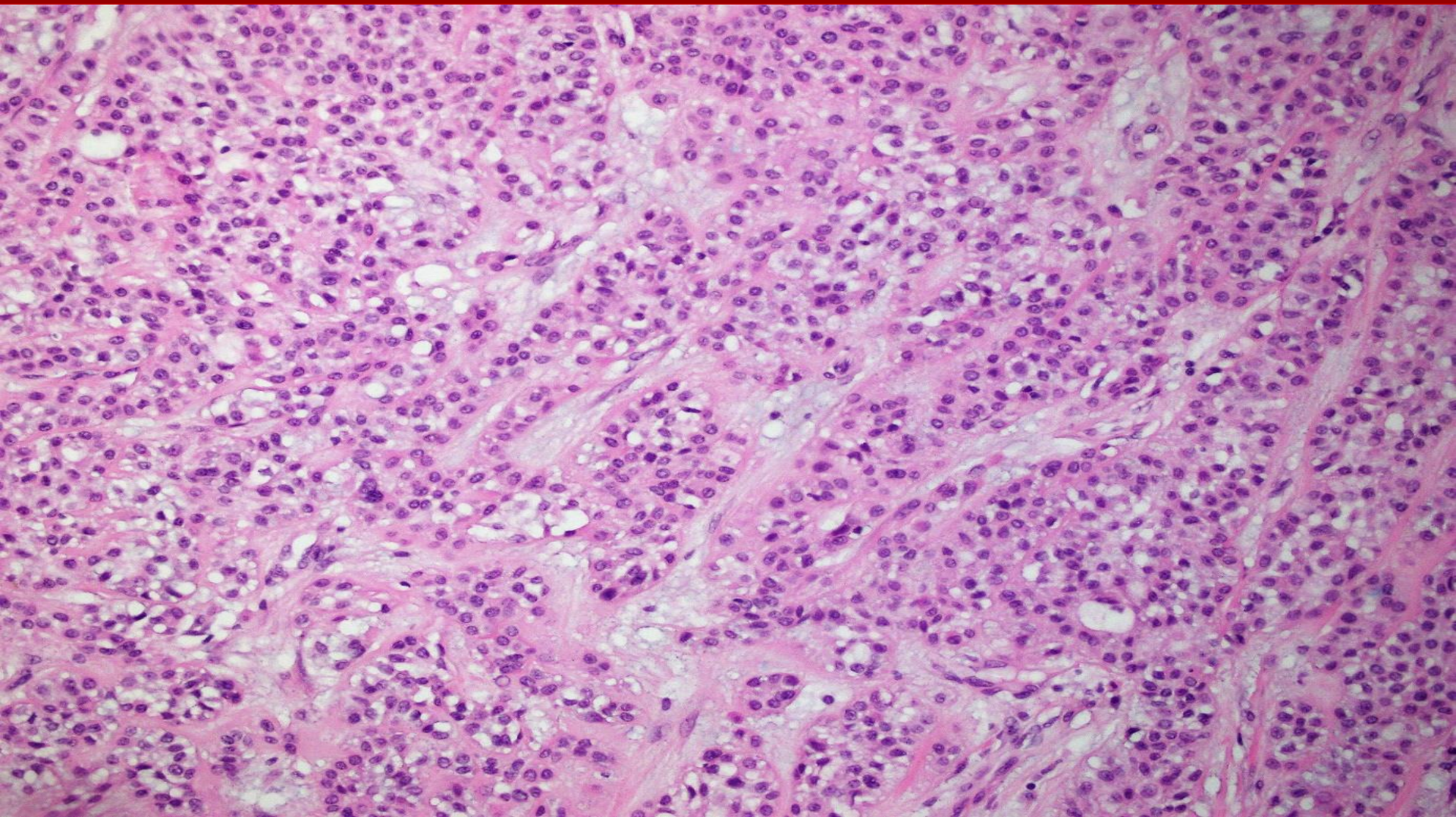


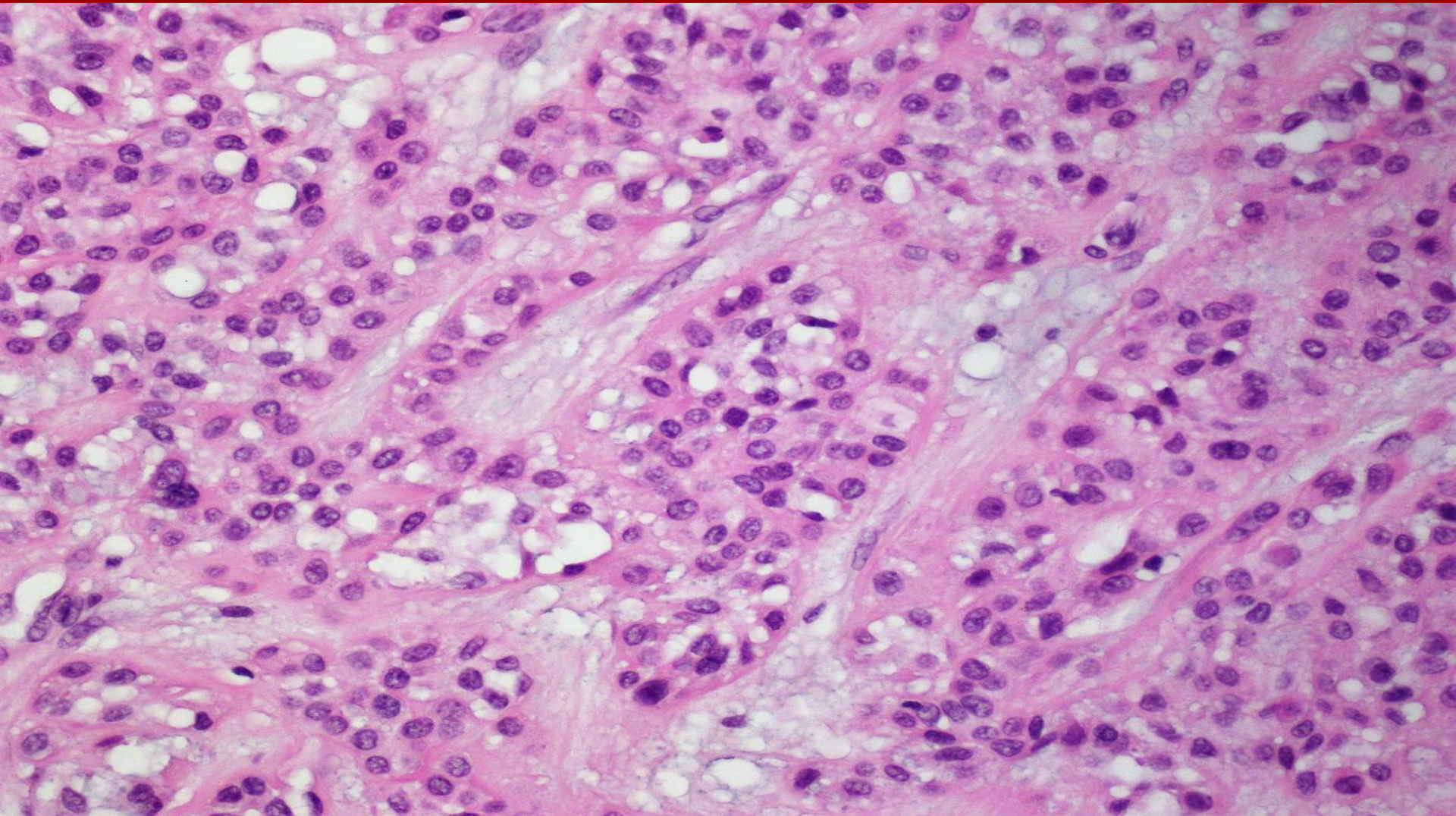
■ Mucoepidermoid Carcinoma











MUCOEPIDERMOID CARCINOMA, LOW GRADE



Cytological Features

- lavender mucin in the background
- Mucus cells (predominant in low-grade)
- Epidermoid cells (predominant in high-grade)
- Intermediate cells



Histological features

- Cords, sheets and clusters of mucous, squamous, intermediate and clear cells
- Occasional focal sebaceous cells, oncocytic change, inflammatory reaction to extravasated mucin or keratin
- No squamous cell carcinoma in situ



Histological Features

■ **Low grade:**

- ✓ Usually cystic
- ✓ abundant mucinous and intermediate cells with bland nuclei lining the glandular spaces
- ✓ Focal nests of epidermoid cells

■ **High grade:**

- ✓ solid and infiltrative growth pattern
- ✓ < 20% intracystic component
- ✓ atypical epidermoid and intermediate cells with cytoplasmic clearing and small number of mucinous cells



Favored system for grading

■ AFIP point system:

- 2 points if < 20% intracystic component
- 2 points if neural invasion
- 3 points if necrosis
- 3 points if 4+ mitotic figures/10 HPF
- 4 points if anaplasia



- **Low grade** if total score is 0 - 4 points
- **intermediate grade** if 5 - 6 points
- **high grade** if 7+ points



Chromosomal alteration

Gene fusion/rearrangement

- t(11;19)(q21;p13)
- t(11;15)(q21;p26)
- CTRC1-MAML2
- CTRC3-MAML2

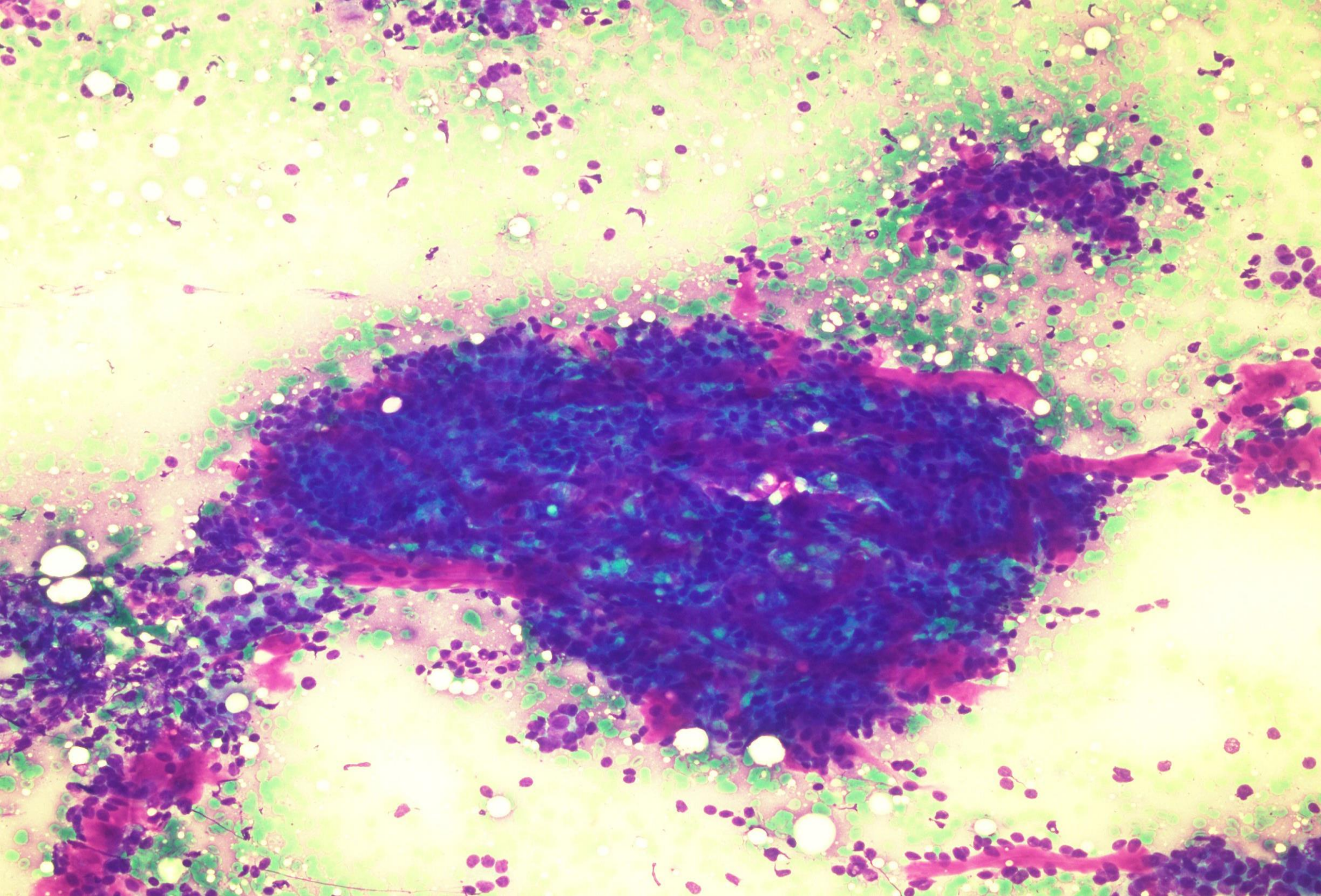


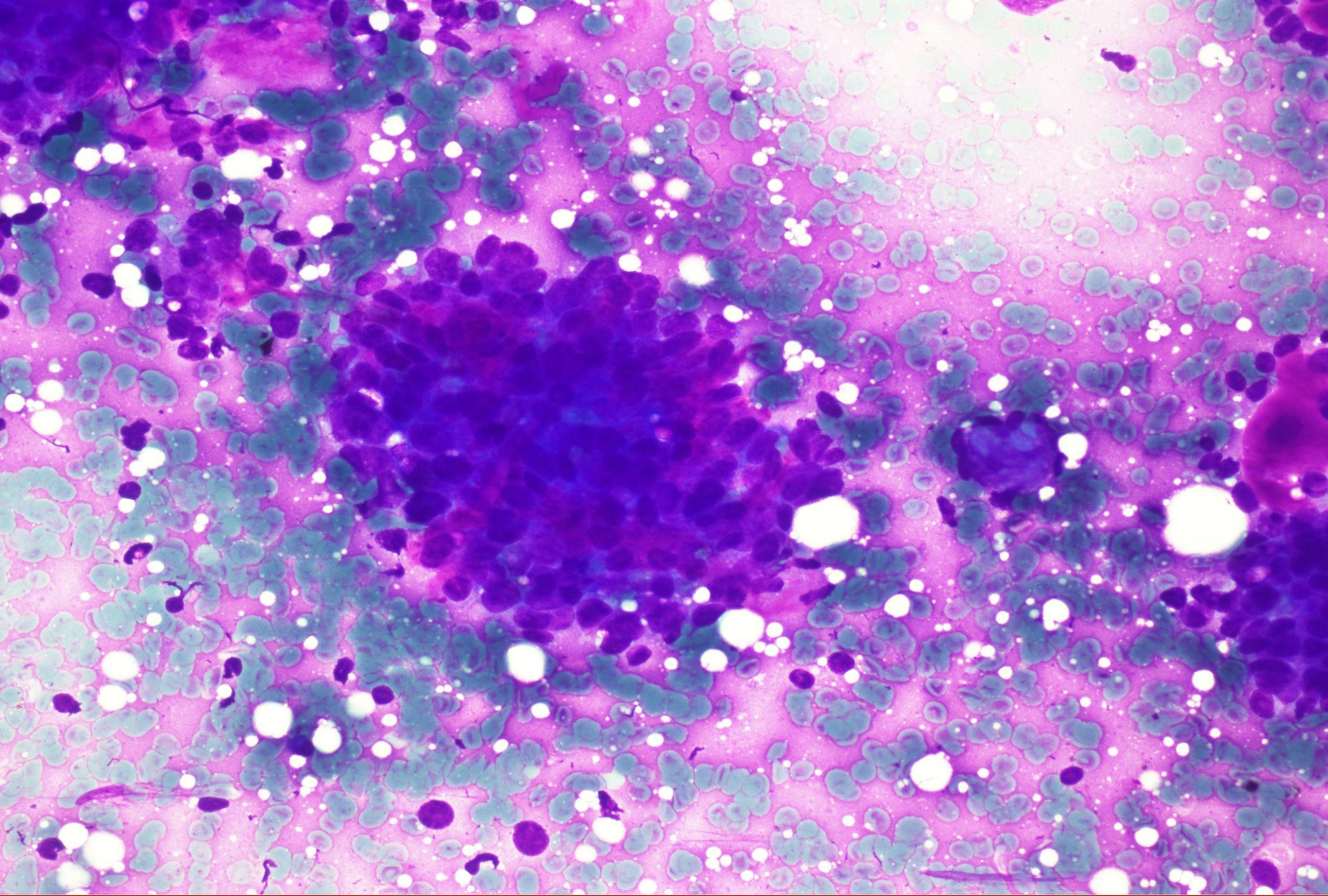
Case no 5

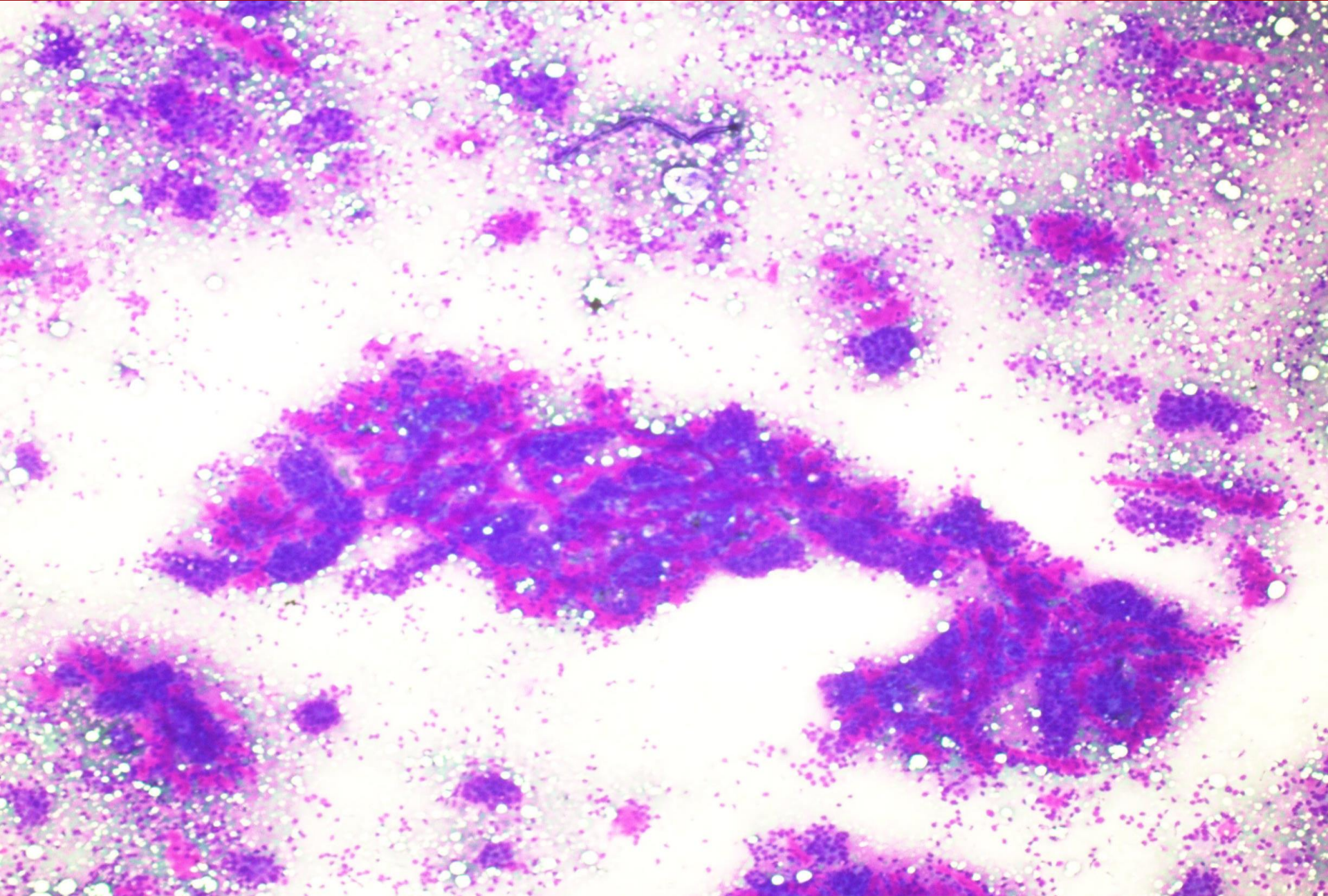
28 female

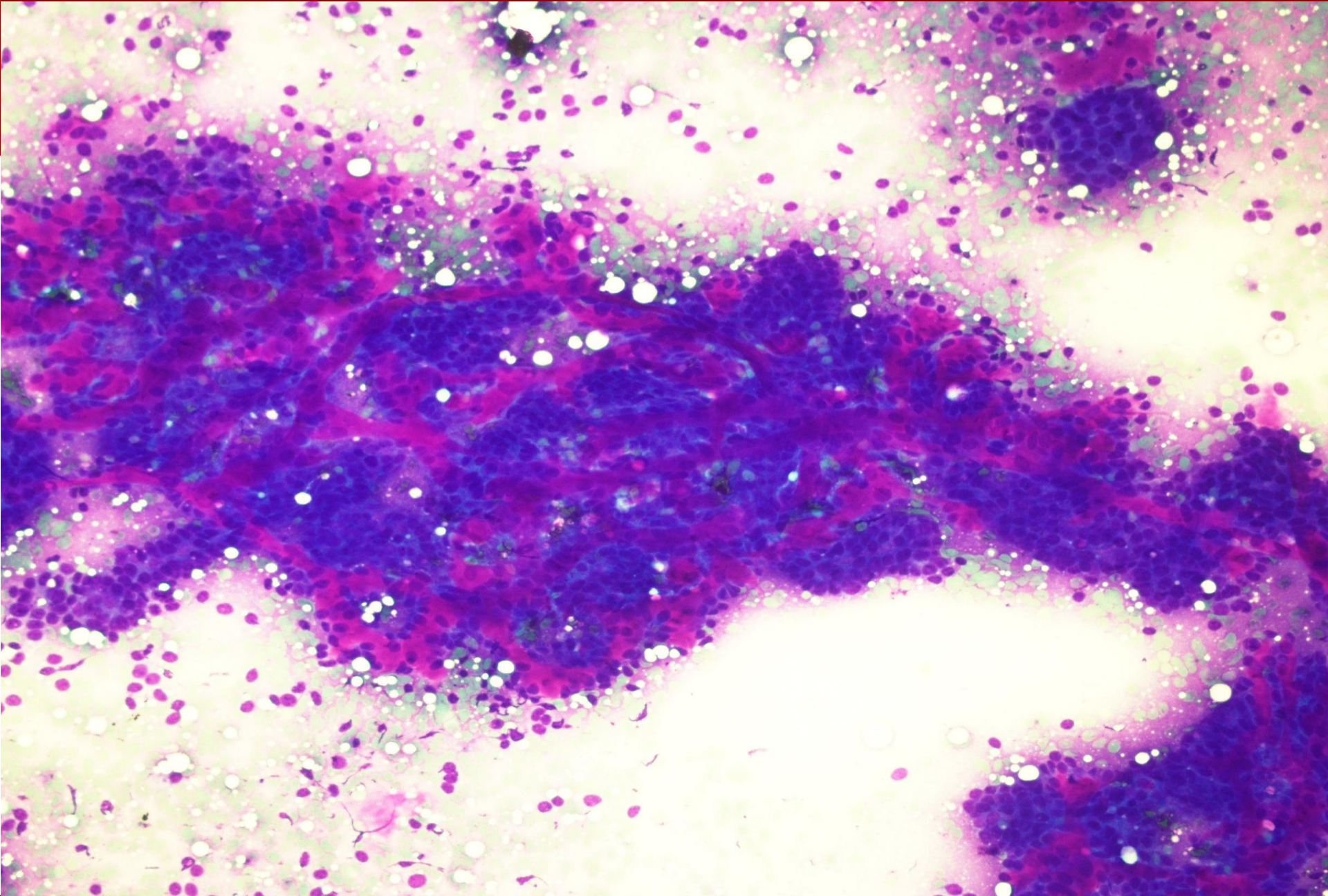
Parotid gland swelling

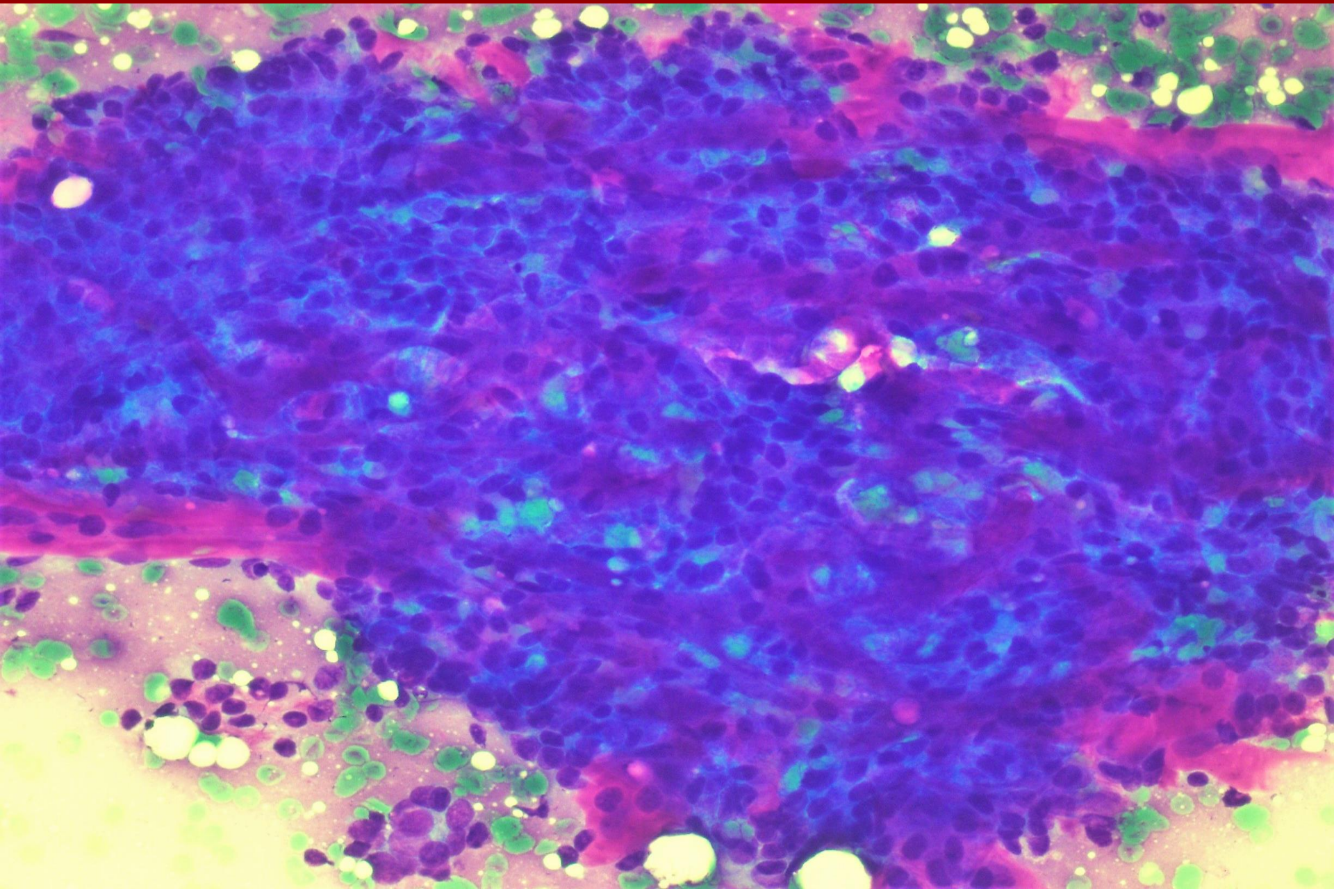


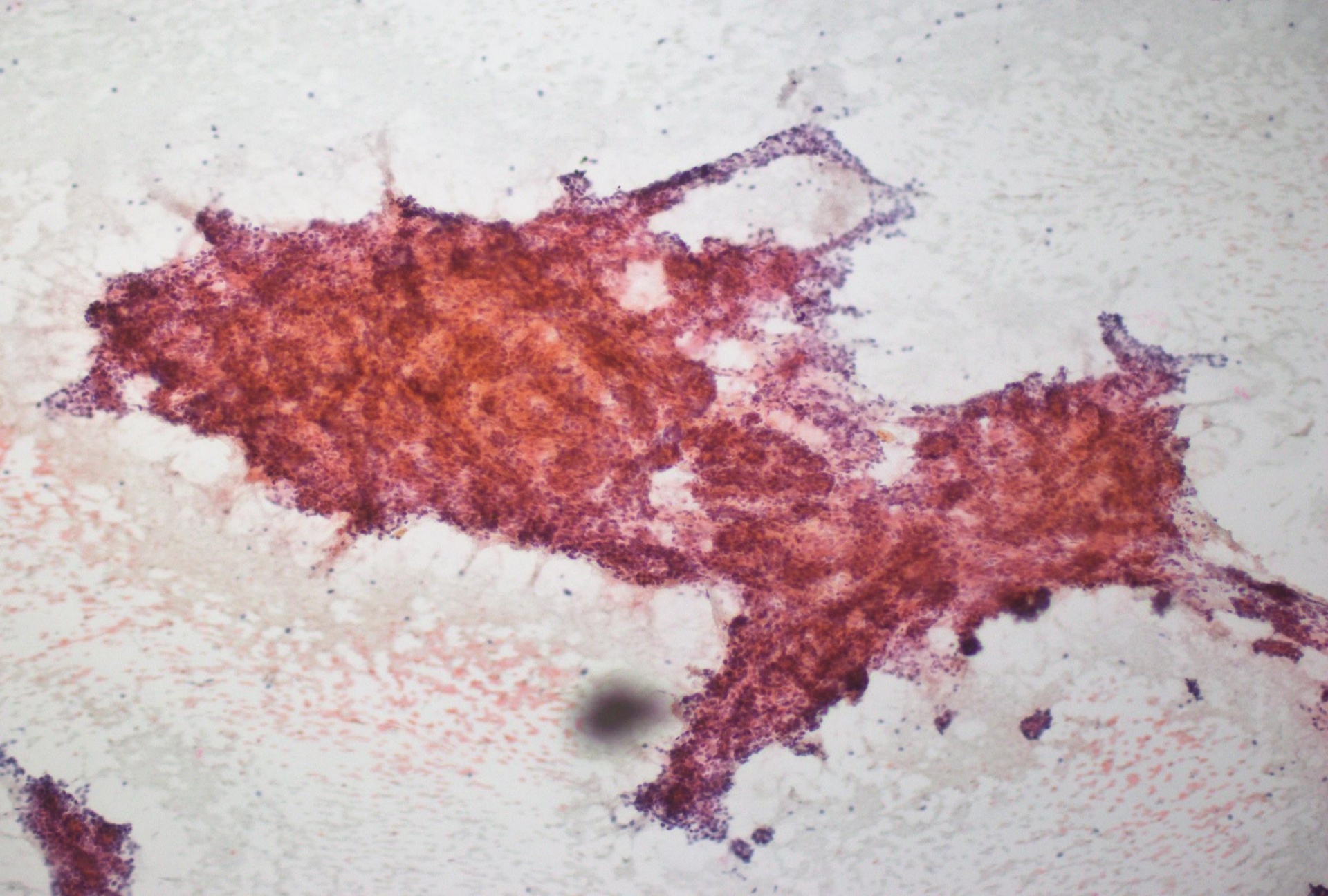


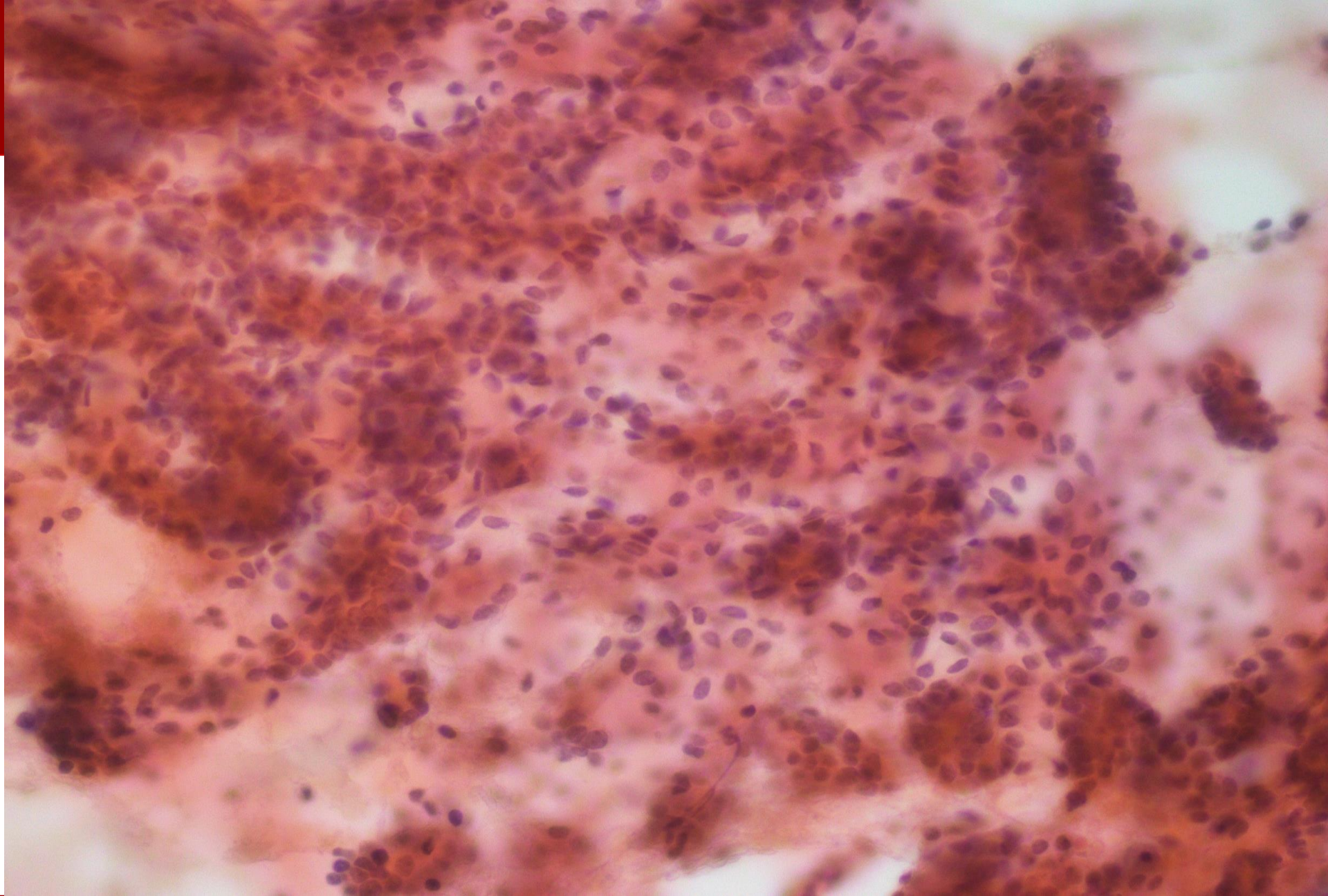












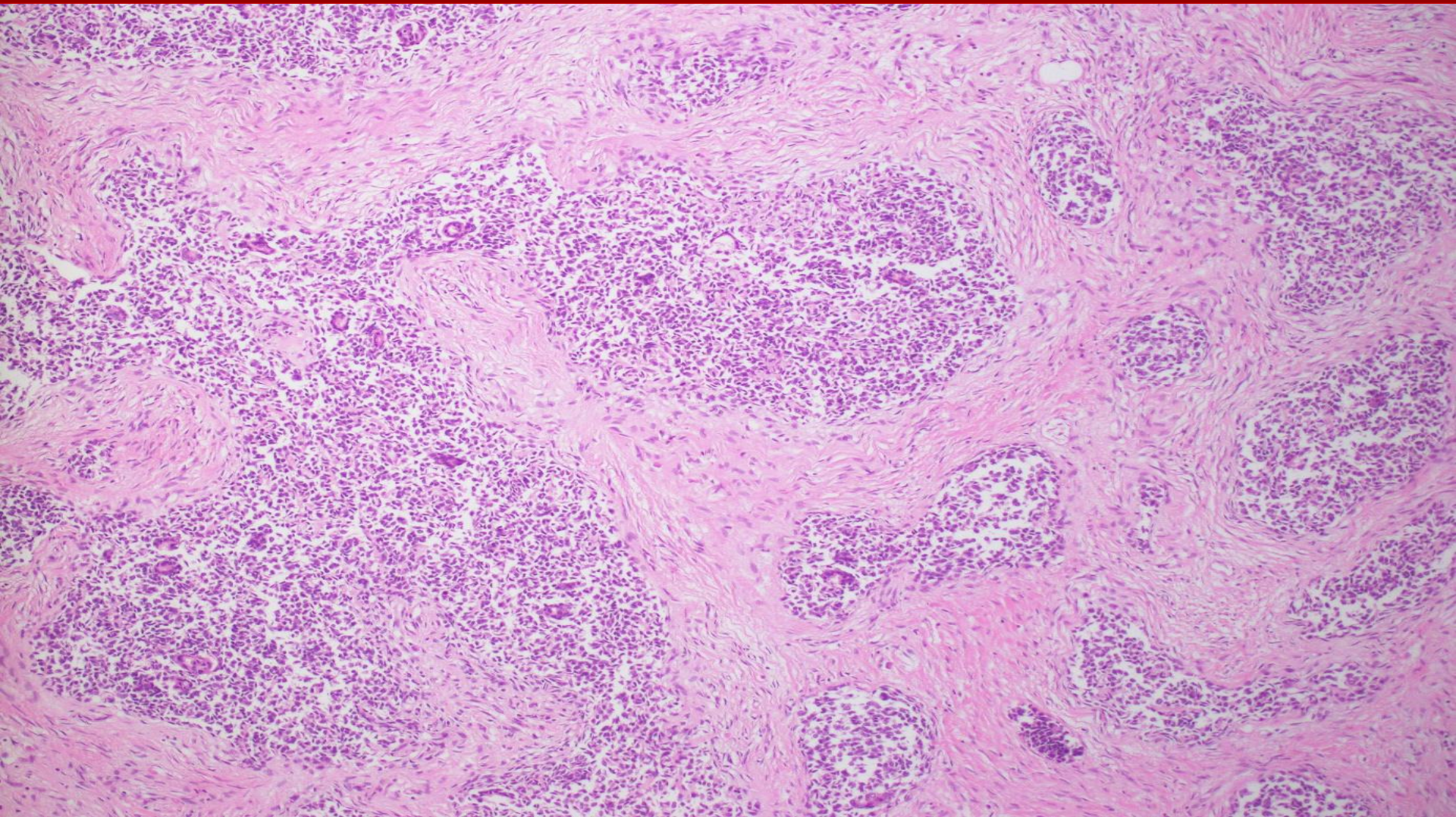
Differentials

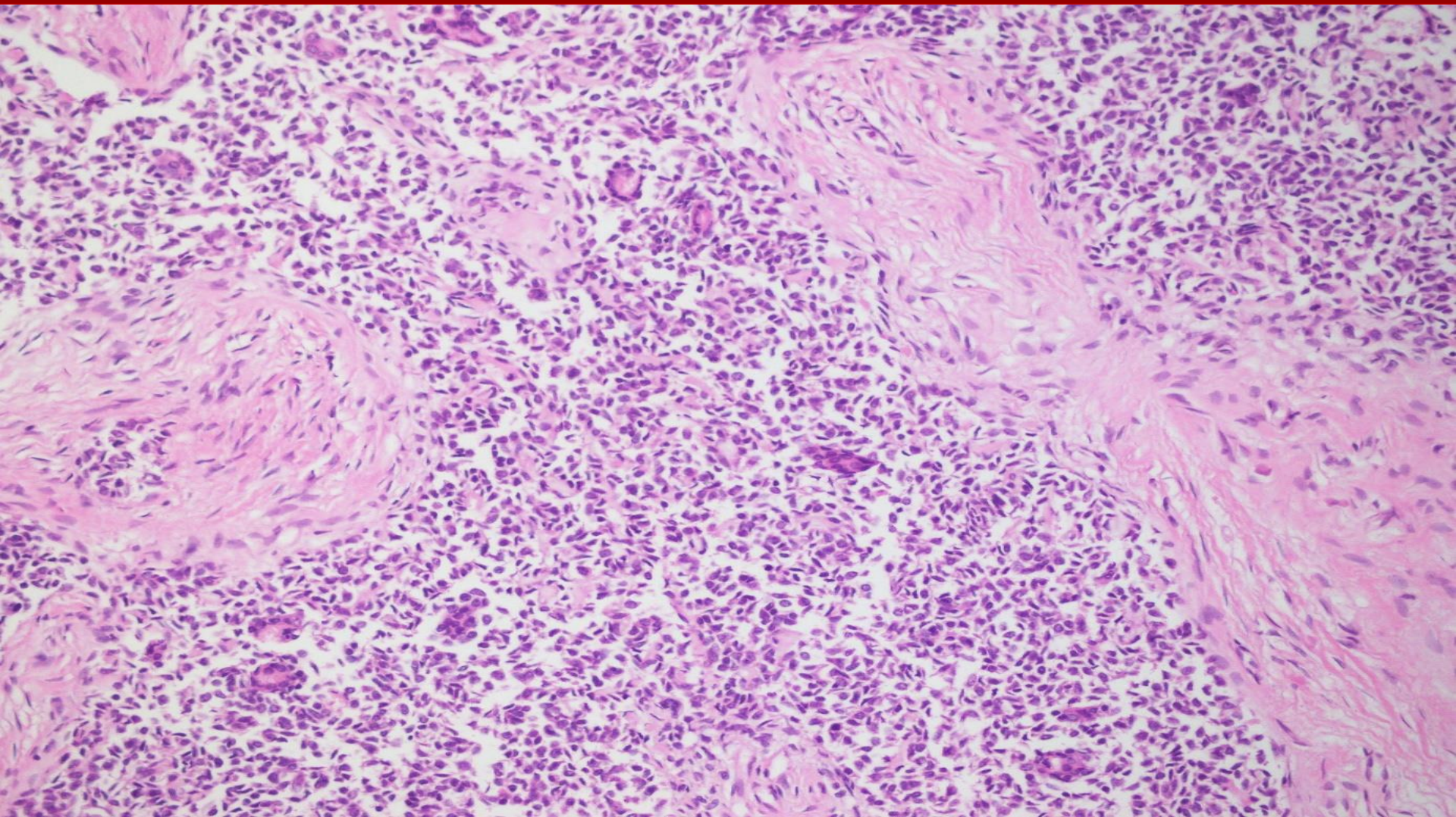
- Adenoid cystic carcinoma
- Basaloid neoplasm
- Myoepithelial neoplasm
- Pleomorphic adenoma
- Polymorphous adenocarcinoma
- Epithelial myoepithelial neoplasm

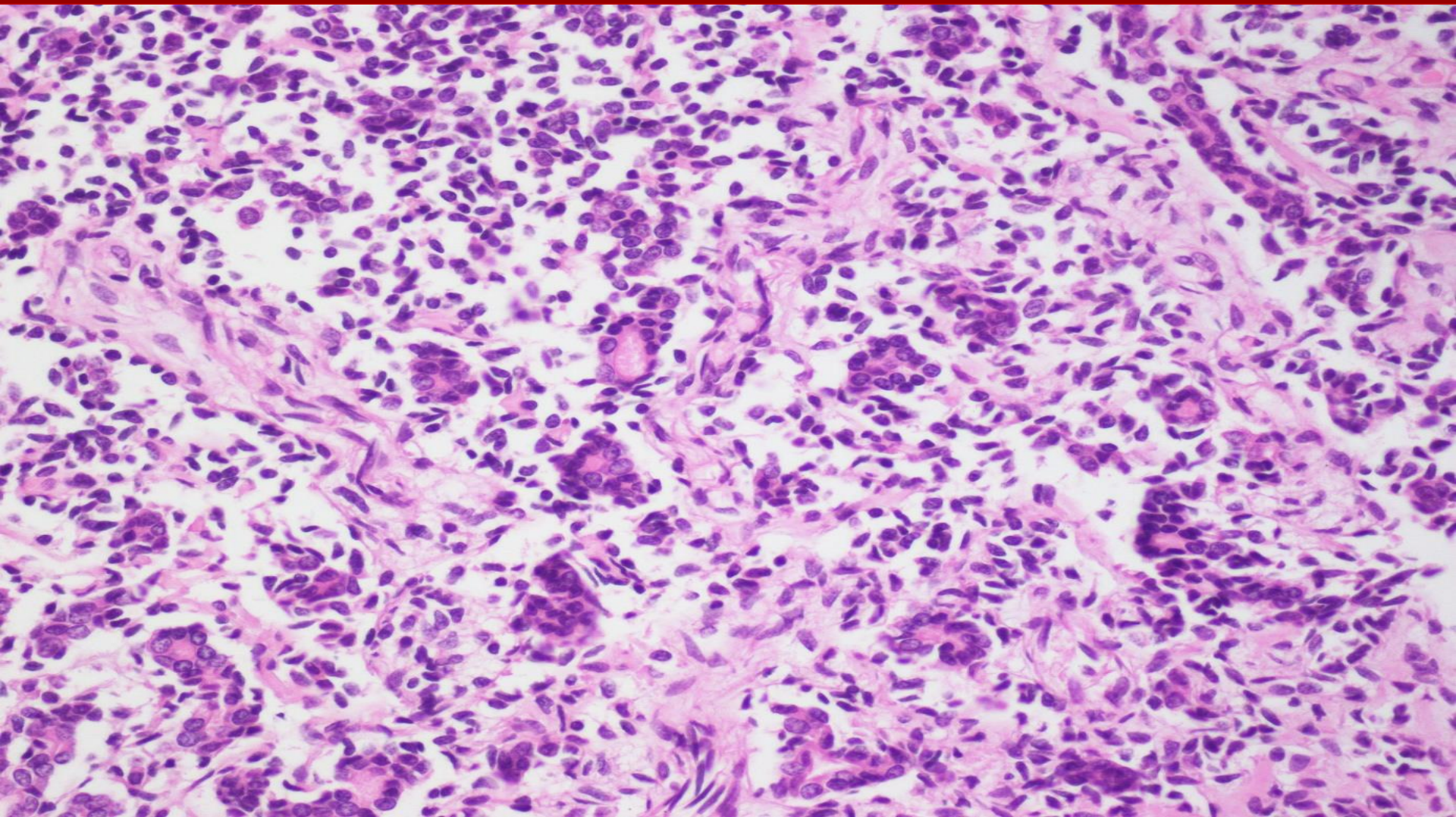


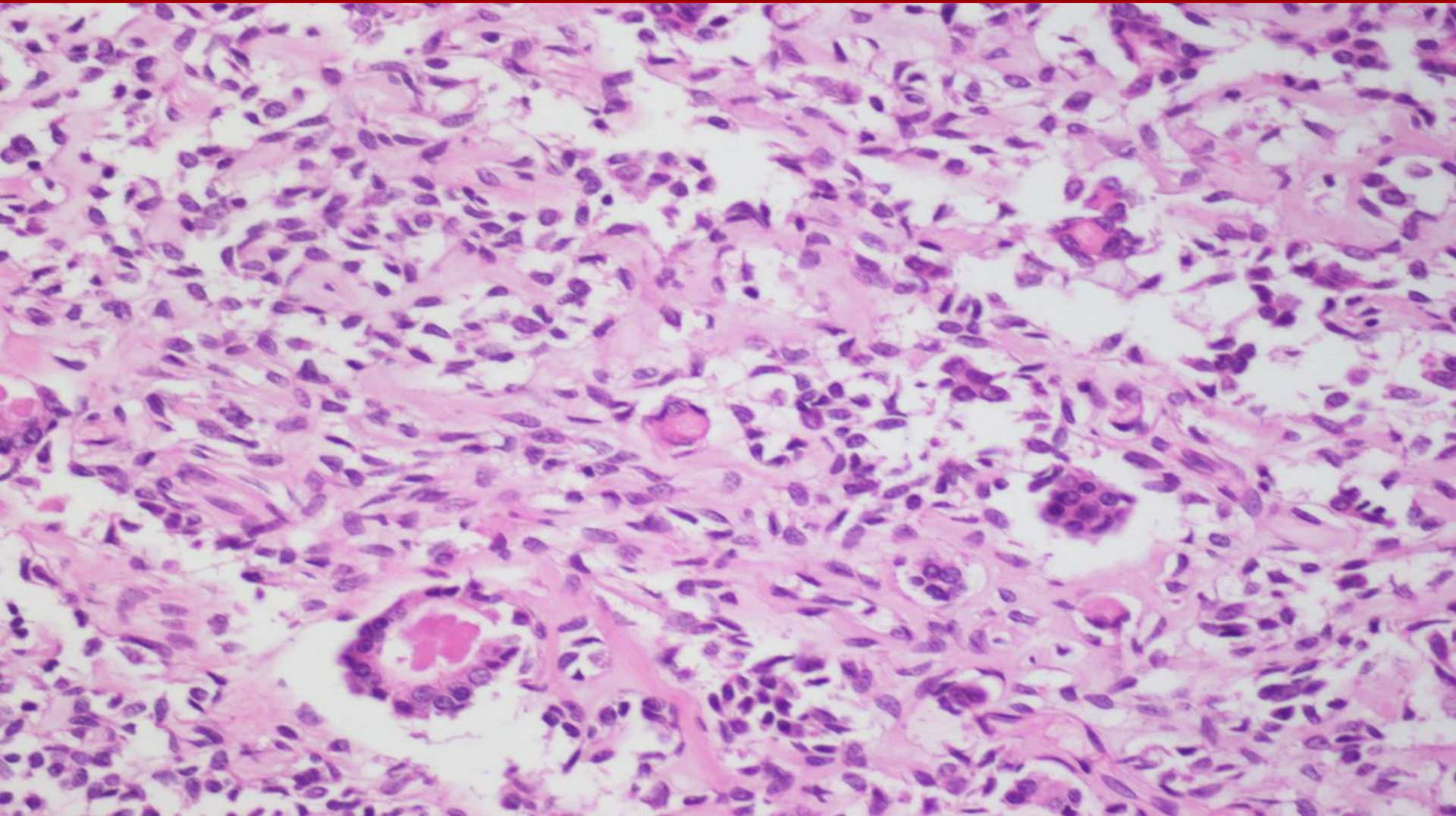
■ Epithelial Myoepithelial Neoplasm



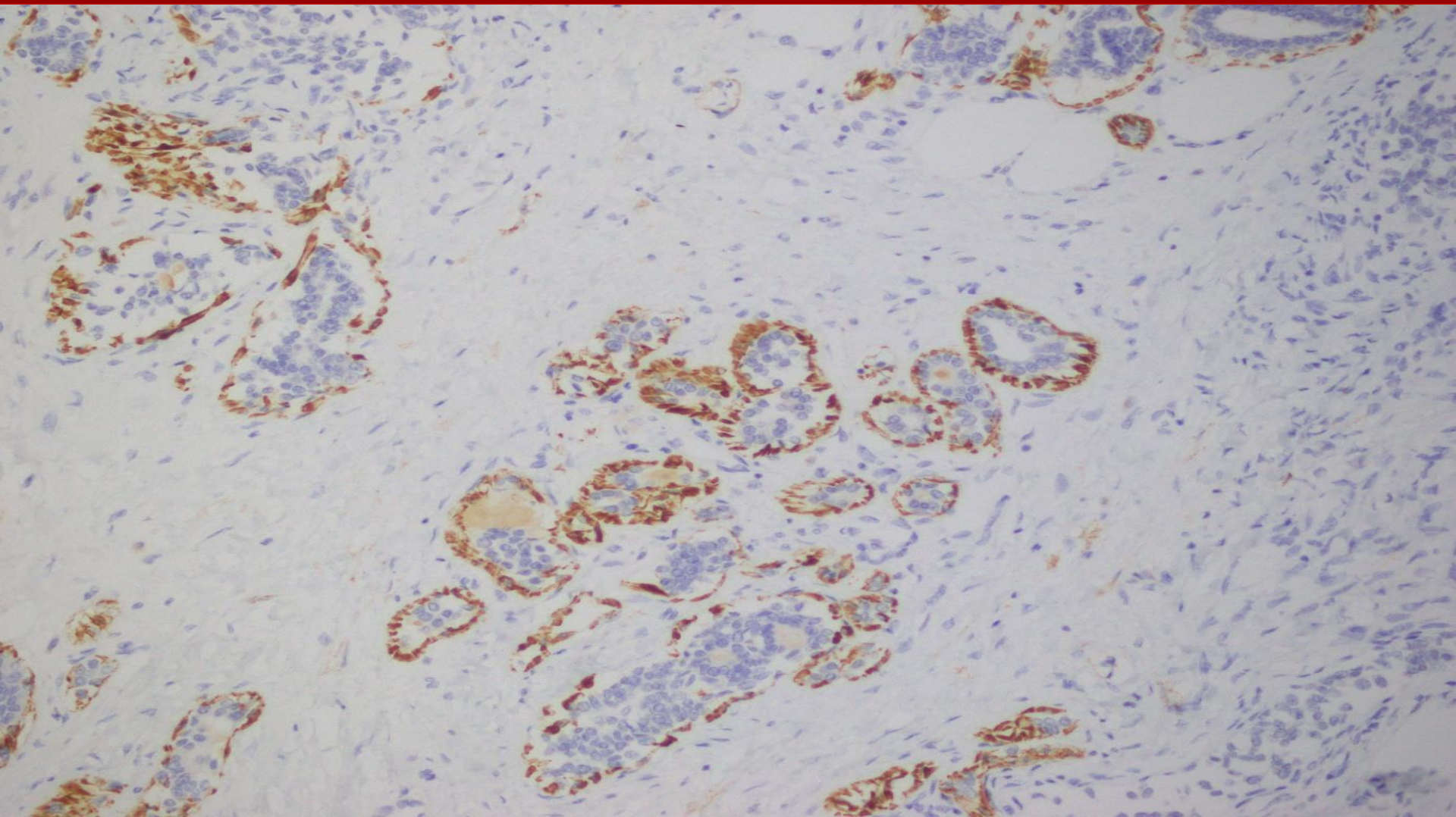




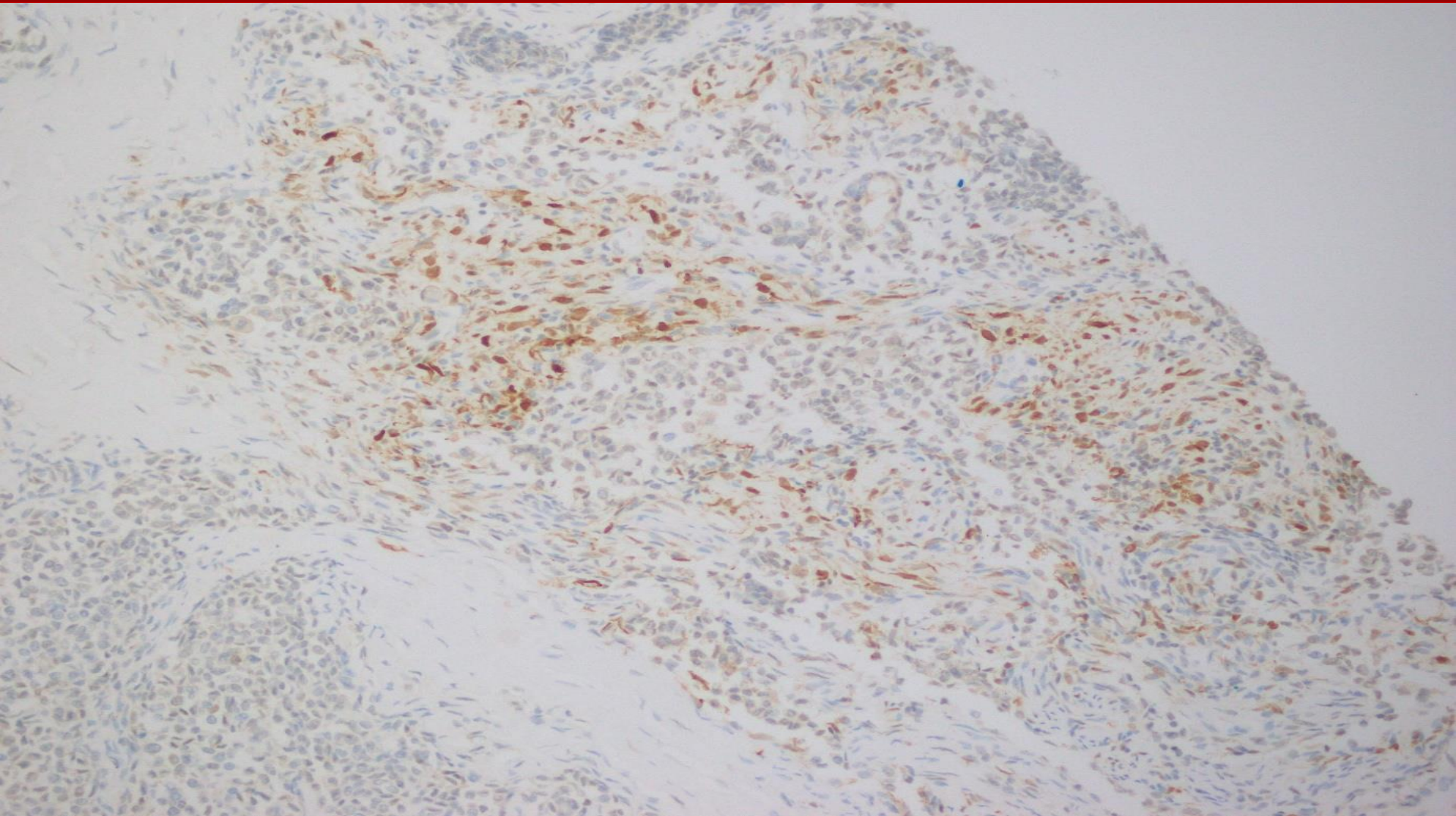




p63



EMA



EPITHELIAL MYOEPITHELIAL CARCINOMA



Clinical Features

- < 0.5% of salivary gland tumors
- Common in parotid gland (80%)
- Mean age 60 years
- More common in women



Cytological Features

- Cellular
- Biphasic pattern
- Clear cells have fragile cytoplasm and appear as single naked nuclei



Histological features

- Multinodular with variable thick fibrous capsule
- Biphasic pattern (epithelial and myoepithelial cells)
- Myoepithelial cells have clear cytoplasm
- Epithelial ductal cells are dark with scant cytoplasm and round bland nuclei
- Often mild nuclear pleomorphism



Immunohistochemistry

- **Myoepithelial component:**

PAS+ diastase sensitive due to cytoplasmic glycogen; **S100, p63, SMA, smooth muscle myosin heavy chain, calponin**

- **Epithelial component:**

Keratin, mostly low-molecular-weight cytokeratins and EMA (usually strong)



Differential Diagnoses

- **Clear cell carcinoma**
 - Effects minor glands
 - Unencapsulated
 - Negative for myoepithelial markers
- **Metastatic renal cell carcinoma**
 - PAX 8 positive
- **Myoepithelial carcinoma**
 - lacks epithelial component
 - Negative for epithelial markers
- **Pleomorphic adenoma**
 - Biphasic but with prominent myxochondroid stroma
 - Myoepithelial cells usually lack cytoplasmic clearing



Adenoid cystic carcinoma

- prominent cribriform pattern

Polymorphous low grade adenocarcinoma

- affects intraoral salivary glands,
- clear cells do not predominate,
- not associated with ductal cells



Thank you

